









Clinical Reports

## Post-traumatic calcaneal tenorrhaphy associated to plaque and external skeletal fixative in dog: case report

Tenorrhafia calcânea pós-trauma associada ao uso de placa e fixador esquelético externo em cão: relato de caso

Trayse Graneli Soares<sup>1\*</sup> , Leonardo Palhares Cardoso<sup>2</sup> , Isabel Rodrigues Rosado<sup>1</sup> , Ian Martin<sup>1</sup> , Marina Cazarini Madeira<sup>1</sup> , Endrigo Gabellini Leonel Alves<sup>1</sup> 

<sup>1</sup> Programa de Pós-Graduação em Sanidade e Produção Animal nos trópicos - Mestrado (Universidade de Uberaba)

<sup>2</sup> Médico Veterinário autônomo

### ARTICLE INFO

*Article history*

Received 29 June 2020

Accepted 08 September 2020

*Keywords:*

Orthopedy

Modified Kessler

Surgery

*Palavras-chave:*

Ortopedia

Kessler modificado

Cirurgia

### ABSTRACT

The common calcaneal tendon is one of the most injured tendons in dogs. Regardless the cause, if untreated, the injury may increase permanently compromising the injured limb function. This is a case reported in a seven years old, male, 31.5 Kg, very hectic behavior, Labrador dog. The dog had been suffered a cut by walking on a wasteland. At the clinical examination, he presented claudication, knee hyperextension and tarsal hyperflexion. At the common calcaneal tendon palpation, a loss of continuity was realized characterizing a rupture. The injury was surgically treated by approximating the tendon's stumps. Aiming to reduce the tension over the tendon, a plaque was sutured in the tendon caudal surface and the tarsocrural joint was temporarily immobilized. The calcaneal tenorrhaphy with modified Kessler suture associated to an orthopedical plaque and external skeletal fixative showed to be efficient to promote a dog's common calcaneal tendon early repairing. The healing occurred by first intention and the injured limb had a deambulatory restoration even in the first postoperative week. Such conducts have also to be considered in calcaneal tenorrhaphies in active, heavy and/or uncooperative patients.

### RESUMO

O tendão calcâneo comum é um dos tendões mais lesionados em cães. Independente da causa, se não tratada, a lesão pode evoluir comprometendo permanentemente a função do membro acometido. Este relato é de um caso ocorrido em um cão, macho, labrador de 31,5 kg, sete anos de idade, com temperamento muito agitado. O cão tinha histórico de ter se cortado ao andar em um terreno baldio. No exame clínico foi observada claudicação, hiperextensão do joelho e hiperflexão do tarso. À palpação do tendão calcâneo comum foi percebida a perda de continuidade caracterizando ruptura. A lesão foi tratada cirurgicamente aproximando-se os cotos do tendão. Para reduzir a tensão sobre o tendão foi suturada uma placa na superfície caudal do tendão e a articulação tarsocrural foi temporariamente imobilizada. A tenorrhafia calcânea com sutura de Kessler modificada em associação ao uso de placa ortopédica e fixador esquelético externo, mostraram-se eficientes em proporcionar reparação precoce do tendão calcâneo comum de cão. A cicatrização ocorreu por primeira intenção e houve restabelecimento deambulatório do membro acometido já na primeira semana pós-operatória. Estas condutas também devem ser consideradas em tenorrhafias calcâneas de pacientes ativos, pesados e ou pouco colaborativos.

### INTRODUCTION

At the small animals clinic, muscles and tendons have significant participation on domestic dogs orthopedical problems, being the tendon injuries, in general, most debilitating than muscular injuries, normally with

decreased capacity of injury spontaneous resolution (TOBIAS; JOHNSTON, 2011). Due to factors such as low vascularity, oxygenation and nutrition, the tendon tissue has limited regeneration capacity. The common calcaneal tendon complete healing can take from months to years. The tendon primary recovering takes around

\* Corresponding author: [traysegraneli@gmail.com](mailto:traysegraneli@gmail.com)

six weeks, necessary time as it acquires resistance to then perform force transmission. It is fundamental that it remains protected by immobilizer methods in such period (OLSSON; PIPPI, 2017). The most clinical affected tendons in small animals are avascular, such as the common calcaneal tendon (SLATTER, 2009). The common calcaneal tendon, also known as Achilles tendon, consists in the junction of the gastrocnemius muscle tendons, femoral biceps muscle common tendon, both semitendinosus and gracilis together and superficial digital flexor muscle tendon. The gastrocnemius muscle tendon is the tarsal extensor mechanism main component (FOSSUM et al., 2014; PIERMATTEI; FLO; DECAMP, 2009), as the most of injuries are related to such tendon trauma. The common calcaneal tendon rupture can be classified regarding its severity (CORR et al., 2010), with a partial or total compromising, caused by cutting objects, running over, fights (BUTLER, 1985) and still associated to diabetes and/or obesity (PIERMATTEI; FLO; DECAMP, 2009). Animals that perform excessive efforts or even improper effort due to claudication are subjected to the tendon rupture (VALLIN, 1999). The animal with a common calcaneal tendon rupture or avulsion presents clinical signs such as claudication, plantigrade support, maybe not supporting the affected limb for days (PIERMATTEI; FLO; DECAMP, 2009). Still, among the common calcaneal tendon insufficiency classical signs, highlights the tarsal hyperflexion and the knee hyperextension, significantly interfering in the animal locomotion, suspecting of rupture or avulsion (BLOMBERG, 1998). The treatment must be exclusively surgical and should be performed the earlier as possible (PIERMATTEI; FLO; DECAMP, 2009).

This report aims to describe conducts on solving common calcaneal tendon trauma in patients with severe locomotor injury. Approaching clinical, surgical, and postoperative aspects, as well as describing the orthopedic plaque use and temporary immobilization with external skeletal fixative, for treating and supporting the dog calcaneal tenorrhaphy.

### CASE REPORT

A seven years old, male, 31.5 Kg, Labrador dog, with a very hectic behavior was seen at the Veterinary Hospital of Uberaba. At the anamneses, the tutor related that the animal had a cut at the right calcaneal region 10 days ago and since then began to claudicate. The wound was treated and healed by second intention, however the animal persisted claudicating and with right pelvic limb in plantigrade support. Reported a treatment with carprofen 4.4 mg.kg<sup>-1</sup> (Carproflan®, Agener União, Brazil) via oral (VO), *s.i.d.* for 5 days and, cephalixin 30 mg.kg<sup>-1</sup> (Celesporin®, Ourofino Saúde Animal Ltda., Brazil) VO, *b.i.d.* for 10 days, presenting improvements only in the edema and the wound.

At the general clinical examination, it was estimated a body score of three, hydrated, capillary perfusion time of 2 seconds, cardiac frequency of 130 beat per minute and

rectal temperature of 38.4 °C. The locomotor system specific evaluation highlighted a right pelvic limb claudication, knee hyperextension and tarsal hyperflexion. Palpating the common calcaneal tendon, the lack of continuity was noted characterizing total rupture with the tendinous structural stumps ends separation and volume increase. A radiographic evaluation was performed on the right tarsocrural joint as for exclude possible associated osteoarticular pathologies. The clinical findings, added to the radiographical results, funded the common calcaneal tendon rupture diagnostic, being indicated the tenorrhaphy for solving. Blood aliquots were collected for preoperative biochemical and hematological exams, which did not evidence changes that contraindicated the proposed surgical conduct.

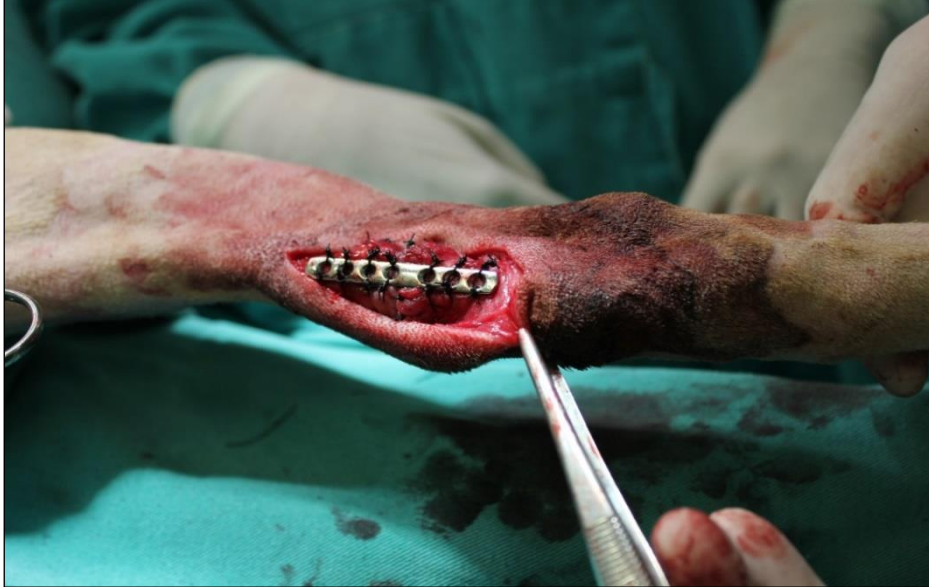Preoperatively, the animal was subjected to a 2 hours water fasting and 8 hours food fasting. The trichotomy was performed at the affected limb, followed by operative field antiseptics with degerming chlorhexidine 2% (Riohex 2%®, Rioquímica, Brazil) and alcoholic chlorhexidine 0.5% (Riohex 0,5%®, Rioquímica, Brazil). For the preanesthetic protocol, 0.05 mg.kg<sup>-1</sup> of acepromazine (Acepran®, Vetnil, Brazil) and 0.5 mg.kg<sup>-1</sup> of morphine (Dimorf®, Cristália Produtos Químicos Farmacêuticos Ltda, Brazil) were used, intramuscular (IM). For the epidural block, 0.13 mL.kg<sup>-1</sup> of lidocaine 2% (Xylestesin®, Cristália Produtos Químicos Farmacêuticos Ltda., Brazil), 0.13 mL.kg<sup>-1</sup> of bupivacaine 0.5% (Neocaina®, Cristália Produtos Químicos Farmacêuticos Ltda, Brazil) and, 0.01 mg.kg<sup>-1</sup> of morphine (Dimorf®, Cristália Produtos Químicos Farmacêuticos Ltda., Brazil) were used. The anesthetic induction was performed with 5 mg.kg<sup>-1</sup> of ketamine (Cetamin®, Syntec, Brazil) associated to 0.5 mg.kg<sup>-1</sup> of diazepam (Compaz®, Cristália Produtos Químicos Farmacêuticos Ltda, Brazil), all them intravenously (IV). The anesthetic plan maintenance was performed with isoflurane (Isoforine®, Cristália Produtos Químicos Farmacêuticos Ltda., Brazil) diluted in oxygen 100%. During the trans-surgical period, together with the sodium lactate ringer (Ringer com Lactato, JP Farma, Brazil), an 3 mL.kg<sup>-1</sup>.h infusion of meloxicam 0.2 mg.kg<sup>-1</sup> (Maxicam®, Ourofino Saúde Animal Ltda, Brazil) and cephalixin 30 mg.kg<sup>-1</sup> (Rilexine®, Virbac, Brazil) was administered.

The dieresis by lateral longitudinal incision over the common calcaneal tendon was indicated. Divulsion until exposing the tendinous segments was performed, visualizing *in locus* the presence of fibrosis in both the tendinous stumps. The excess of fibrous tissue was transversely sectioned as to normalize the rupture surface removing around 0.5 cm of tissue. For the synthesis, a nylon wire 0 (Mononylon Ethilon®, Johnson & Johnson, Brazil) was used, applying modified Kessler standard suture for approximating the tendinous stumps; afterwards, a standard in separate single suture was performed with a nylon 2-0 (Mononylon Ethilon®, Johnson & Johnson, Brazil), aiming to improve the tendinous edges apposition. Besides of using the wires, a neutral 2.0 mm metallic plaque fixation was

incorporated to the surgical conduct, in steel (L318), with seven holes, at the tenorrhaphy area (Figure 1), aiming to provide higher stability to the calcaneal tendinous repairing, executing two separated single

sutures embracing about half of the tendinous tissue in thickness, for each plaque hole, with nylon 2-0 (Mononylon Ethilon®, Johnson & Johnson, Brazil).

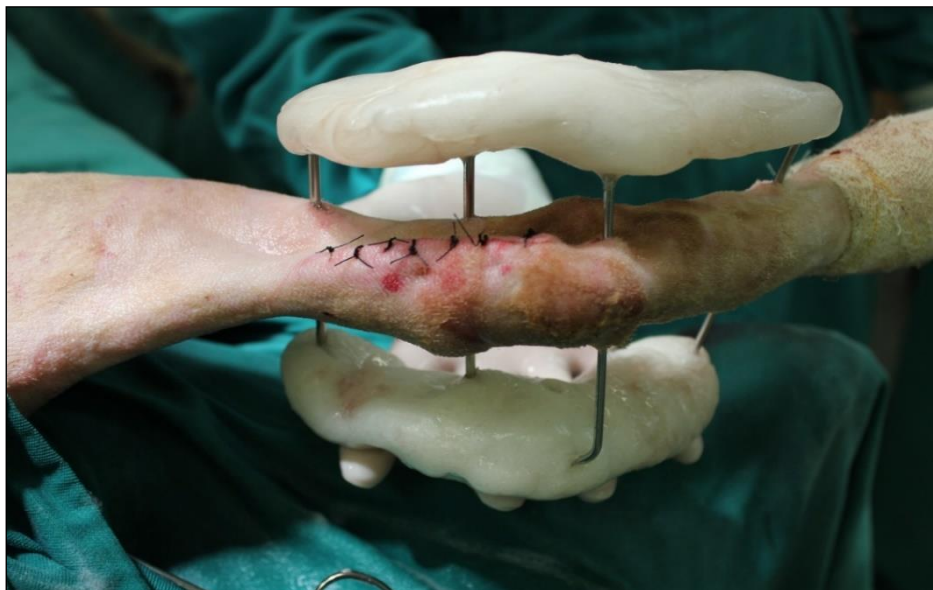Figure 1. Tenorrhaphy trans-surgical photographic illustration performed in dog with common calcaneal tendon rupture. It becomes visible the metallic plaque fixated with separated single standard sutures to the tendon, immediately after the tenorrhaphy procedure.



By finishing the tenorrhaphy, an external skeletal fixative was incorporated to promote the tarsocrural joint temporary immobilization, using for that four central threaded pins with 2.5 mm of diameter, being to in the tibia, one in the calcaneal and one in the metatarsus. As an external fixative bar, the polymethylmethacrylate was used. The external skeletal fixative (Figure 2) was kept for 75 days. The

subcutaneous synthesis was performed with absorbable, sterile, synthetic surgical suture wire copolymer compound obtained from Glycolide and Lactide, coated with Polyglactine 370, 2-0 caliber (Vicryl®, Johnson & Johnson, Brazil) in continuous single standard and, the skin synthesis in separated single standard using nylon 2-0 (Mononylon Ethilon®, Johnson & Johnson, Brazil).

Figure 2. Photographic illustration immediately after the tenorrhaphy surgical procedure in a dog with common calcaneal tendon rupture. In evidence, the external skeletal fixative (2 more proximal pins in the tibia, 1 in calcaneal and 1 in metatarsus) incorporated to promote tarsocrural joint temporary immobilization and tension reduction over the repaired common calcaneal tendon.



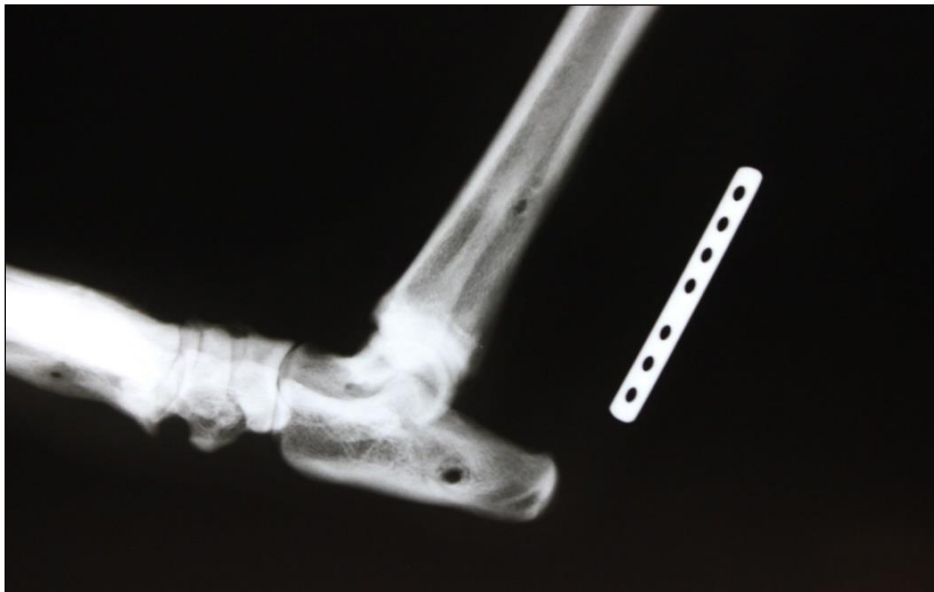For the postoperative it was prescribed cephalexin (Rilexine®, Virbac, Brazil) 30 mg.kg<sup>-1</sup> *b.i.d.* for 7 consecutive days, dipyrone (Dipirona gotas®, Biovet, Brazil) 25 mg.kg<sup>-1</sup> *t.i.d.* for 5 consecutive days, meloxicam (Maxicam®, Ourofino Saúde Animal Ltda, Brazil) 0.1 mg.kg<sup>-1</sup> *s.i.d.* for 5 consecutive days and tramadol hydrochloride (Cronidor®, Agener União, Brazil) 2 mg.kg<sup>-1</sup> *t.i.d.* for 7 consecutive days. The surgical wound healed with no interurrences and the skin sutures were removed after 10 days. At the 30<sup>th</sup> postoperative day, the patient shocked the external fixative in the wall corner with moderated and temporary bleeding throughout the pin holes, besides of considerable claudication. After such occurrence, the patient was medicated with meloxicam (Maxicam®, Ourofino Saúde Animal Ltda, Brazil) 0.1 mg.kg<sup>-1</sup> *s.i.d.* for 5 consecutive days, getting claudication improvement.

After removing the external skeletal fixative, the patient passed through physiotherapy exercises for deambulatory rehabilitation. Within the first 15 days after the external fixative removal, he had some walks to stimulate the animal support and, after these period,

some light exercises were daily made, even light running and stretching. Besides that, three times a week, the animal's been done nine hydrokinesiotherapy exercises in a pool. After 30 days from the external skeletal fixative removal, a control radiography was performed to evaluate the plaque positioning fixated to the right calcaneal tendon (Figure 3) or probable changes that could occur.

The tutor was guided to take the patient to re-evaluation each six months and was made aware that although the plaque is made by an inert biomaterial, it may contaminate over time and that it should be removed once it is already useless after the tissue repairing. Since the surgical intervention, the patient has been evaluated each 6 months and, until the present moment (2 years after the surgical intervention, approximately) none change was observed at the patient clinical examination. However, the tutor has not allowed to proceed radiographical exams and chose for not remove the plaque until some change happens in the operated region.

Figure 3 - Tibia-tarsal region radiographical image illustration, with laterally medium x-ray incidence, 105 days after the tenorrhaphy in dog with common calcaneal tendon rupture. It is observed the orthopedic plaque position fixated to the common calcaneal tendon tunic.



## DISCUSSION

Considering the predictable complexity regarding the healing process and tendinous injury recovering, this report shows that the correct surgical procedure, the tenorrhaphy using an orthopedic metallic plaque associated to the external skeletal fixation, has provided a fast functional recovering of the to the patient's injured limb. The surgical repairing is always indicated in a total tendinous rupture case (FOSSUM et al., 2014), generating good results and with patients recovering the function in 70% to 94.7% of the affected dogs (CORR et al., 2010).

The external skeletal fixator remaining for 75 days shows that in the reported case, there was precocity on tendinous tissue regeneration and returning to physiological ambulence.

It is convenient to highlight that tendons have slow and difficult repairing and, for it to have resistance again and transmit the force generated by its homonymous muscle may take until a six months period. During this period, immobilizing the tarsocrural joint is indispensable (OLSSON; PIPPI, 2017), so that the repair made in the tendon does not break. In this report, besides the modified Kessler standard suture technique, a stainless steel neutral orthopedic plaque was included and fixed by separated single sutures encompassing the tendinous

tunic and about a half of the tendon in thickness and proportioned temporary local joint movements restrictions throughout external skeletal fixation, with central threaded pins and polymethylmethacrylate. Other techniques for the tendinous suture tension reduction and for the tibiotarsal joint temporary immobilization, were already successfully used on repairing the common calcaneal tendon (COSTA NETO et al., 1999; RAISER, 2001). The glycerin preserved bovine peritoneum sutured to the common calcaneal tendon was successfully used for repairing common calcaneal tendinous injuries of dogs with minimal inflammatory reaction, being incorporated to the scar tissue and serving as a foundation for a new tissue development, thus restoring the tendon structure (COSTA NETO et al., 1999). Putting a screw from the calcaneal tubercle until the distal tibia portion can promote the joint movement restriction, necessary to the common calcaneal tendon repairing with minimal invasion (COSTA NETO et al., 1999). However, the fail chances in the screw use are higher when compared to the external fixator, once there is charge distribution among the pins, while in the first technique, all the force is concentrated in the screw. It is believed that it is important, especially in case of big breed patients, agitated and less cooperative, such as the mentioned dog.

Not removing the plaque was a tutor's option due to the anesthetic risk and the costs of a new intervention. However, the medical indication was to remove the implant, once after tissue repairing and the collagen fibers remodeling, the plaque would not promote any additional benefit and, might cause troubles throughout the patient's life. Metallic plaques may cause changes such as metallosis, hypersensitivity reactions, fibrosis (ALVES et al., 2010), adherences and, at not integrate to the adjacent tissue, may have its surface contaminated and colonized by bacteria, especially if implanted in superficial tissues, such as this report. In case of not removing metallic implants, periodic revaluations are recommended as to assure that none of these changes have occurred.

Regarding the tendinous healing process, it is a high complexity phenomenon and many factors dependent, among them, the injured tendon type, the time passed between the diagnostic and the intervention, as well as the surgical technique applied (MORAES, 2003). The sum of a good anamneses with correct and early diagnostic, the surgical technique election, the proper post-operative, are factors that can influence the more satisfactory results, even facing the challenges and difficulties present during the tendinous healing process.

The common calcaneal tendon injury can occur due to an acute traumatic episode or from a tendon chronic progressive stretch. The acute injuries occur after a fall or a piercing-cutting wound (SCHULZ, 2014), such as a cut close to the calcaneal region, related by the tutor and visualized by the veterinary doctor during the animal clinical evaluation. The lesions can also be related to

diabetes endocrine diseases and even obesity (PIERMATTEI; FLO; DECAMP, 2009).

The tendon rupture diagnostic is performed by evaluating and observing classical clinical signs of postural changes, tendon sagging by tarsal flexion, palpable edema in the affected region (BLOOMBERG, 1998; FOSSUM et al., 2014), claudication, difficult of limb support for some days and plantigrade position (PIERMATTEI; FLO; DECAMP, 2009) characterize the tendon rupture. Besides that, the animal is incapable of supporting its weight if the lesion is secondary to an acute trauma and the tendon sagging is saw in tarsal passive flexion, when the knee is extended (SCHULZ, 2014). At this report, at the patient clinical evaluation, right pelvic limb claudication, knee hyperextension, tarsal hyperflexion and common calcaneal tendon loss of continuity were evident; calcaneal tendon rupture classical clinical signs.

The radiography is the complementary exam to discard bone comorbidities (PIERMATTEI; FLO; DECAMP, 2009) and was performed to discard possible osteoarticular diseases. Considering that sciatic nerve injury, tarsal collapse secondary to an immune-mediated arthropathy and congenital tarsal hyperflexion are examples of diseases that can mimic clinical findings of common calcaneal tendon rupture in this specie. The tendon palpation reveals the loss of continuity or an edematous area with rupture, while in patients with congenital tarsal hyperflexion the discontinuity is not evident. By neurological exams, sciatic reflex would be absent or decreased (SCHULZ, 2014).

The tendinous rupture surgical correction is indicated, not being indicated the clinical treatment (FOSSUM et al., 2014). Satisfactory surgical results, generally, reflect acute injuries, fast diagnose and immediate treatment, in this case the surgical one. The common calcaneal tendon rupture surgical treatment in dogs is generally associated to a favorable diagnostic, although a relatively long recovering period, described in 20.2 weeks. Dogs with recent lesions, during less than 21 days can get a better functional result (NIELSEN; PLUHAR, 2006). Therefore, the clinical signs together with the patient's history supported the common calcaneal tendon rupture diagnostic. The surgical treatment was indicated, using the proper suture standard for use in traumatized tendons, auxiliar metallic orthopedical plaque in the calcaneal tendon tunic associated to proper apparel to immobilizing the joint movements throughout an external skeletal fixator.

The modified Kessler suture standard was selected, since in the veterinary medicine this suture standard is considered superior in mechanical assays, when compared to other suture standards (MORAES et al., 2003). Regarding the suture techniques for tendinous anastomoses, they may vary from Bunnel-Mayer, Mason-Allen, interrupted single clamping lace or modified Kessler, doble clamping lace, three laces pulley, Krackow, continuous crossed until far-far-close (FAHIE, 2005).

The applied surgical technique was based on the patient's physical integrity restoring concept. It's known that the older the lesion, more complex is the tenorrhaphy procedure and, the longer the distance between the stumps to be repaired, higher the healing period (JOHNSON, 2005). Considering these factors, the injury was surgically repaired aiming maximum stumps approximation and tension absence, what might be contributed for the surgical wound fast healing, with proper stability to the suture line.

In order to assure the tendon healing and avoiding possible recurrence, an external skeletal fixator was inserted temporarily immobilizing the patient's right tarsocrural joints movements. Nielsen e Pluhar (2006) compared applying the external skeletal fixator to dressing handling (splints or plaster), concluding that the initial tarsocrural immobilization method does not affect significantly the complications rate, the immobilization period, the recovering time and the functional result. The actions immobilization to the repaired tendon relevance, at the post-operative, using the external skeletal fixator was also performed by further authors (PIERMATTEI; FLO; DECAMP, 2009). To Raiser (2000), the tarsocrural joint immobilization for a minimum of 21 days is indicated as important factor to succeed in the tenorrhaphies final result. Throughout the tarsocrural joint immobilization, the proper and necessary stability to the necessary conditions in preserving the patient's surgical conduct results were obtained. Prolonged immobilizations may complicate by necrosis, phlebitis, teno-cutaneous adherences, osteoarthritis, osteoporosis, and muscular complications, such as atrophies or muscular contractures. Also, long time immobilizations can predispose to a new tendon rupture (OLSSON; PIPPI, 2017). Attention must be taken as for not occurring prolonged joint immobilization, what could prevent possible undesirable results.

## CONCLUSIONS

The calcaneal tenorrhaphy with modified Kessler suture associated to the use of orthopedical plaque and external skeletal fixator, considering the conditions described in this report, showed to be efficient in proportionate the dog's common calcaneal tendon early repairing. The healing occurred by first intention and there was the injured limb deambulatory restoration, at the first post-operative week. The described conducts constitute alternatives to be considered, also in calcaneal tenorrhaphies for hyperactive, heavy, and less cooperative patients.

## REFERENCES

ALVES, E.G.L. et al. Emprego experimental da placa de compósito poli-hidroxibutirado/hidroxiapatita na fixação femoral em gatos. *Arquivo Brasileiro de Medicina Veterinária e Zootecnia*. v.62, n.5, p.1128-1134, 2010.

BLOOMBERG, M. Músculos e tendões. In: SLATER, D. Manual de cirurgia de pequenos animais. 2.ed. São Paulo: Manole, 1998, p.2358-2373.

BUTLER, H.C. Surgery of tendinous injuries and muscle injuries. In: NEWTON, C.D., NUNAMAKER, D.M. (Eds.). *Textbook of small animal orthopaedics*. Philadelphia: Lippincott, 1985. cap.68. p.835-842.

CORR, S. et al. Retrospective study of achilles mechanism disruption in 45 dogs. *Veterinary Record*, 167: p. 407- 411, 2010.

FAHIE, M.A. Healing, diagnosis, repair, and rehabilitation of tendon conditions. *Veterinary Clinics of North America: Small Animal Practice*, 35(5), p. 1195-1211, 2005.

FOSSUM, T.W. *Cirurgia de Pequenos Animais*. 4.ed. Rio de Janeiro: Elsevier, 2014. Cap.35, p. 1381.

JOHNSON, A.L.; HULSE.D.A. Tratamento de Lesões ou Doenças Musculares e tendinosas. In: FOSSUM, T.W. *Cirurgia de pequenos animais*. 2. ed. São Paulo: Roca, 2005, cap. 36, p. 1149-1156.

MORAES, J.R.E. et al. Propriedades mecânicas de três padrões de sutura no reparo de tendão do músculo flexor profundo do dedo em equinos. *Brazilian Journal of Veterinary Research and Animal Science*, v. 39, n. 2, 2003.

COSTA NETO, J.M. et al. Tenoplastia Experimental do Calcâneo em Cães com Peritônio Bovino conservado em Glicerina. *Revista Ciência Rural*, v. 29, n. 4, p. 697-703, 1999.

NIELSEN, C.; PLUHAR, G.E. Outcome following surgical repair of achilles tendon rupture and comparison between postoperative tibiotarsal immobilization methods in dogs: 28 cases (19972004). *Veterinary and Comparative Orthopaedics and Traumatology*, 19(4), p. 246-249, 2006.

OLSSON, D.C.; PIPPI, N. Princípios e tratamentos alternativos de lesões tendíneas em cães. *Revista de Ciência Veterinária e Saúde Pública*, v. 4, n. 1, p. 092-109, 2017.

PIERMATTEI, D.L.; FLO, G.L.; DECAMP, C.E. Fraturas e Outras condições Ortopédicas do Tarso, Metatarso e falanges. In: *Manual de ortopedia e tratamento das fraturas dos pequenos animais*. 4. ed. São Paulo: Manole, 2009, cap. 20, p. 760-770.

RAISER, A.G. Reparação do tendão calcaneal em cães. In: VALLIN, I. *Studio delle lesioni tendinee nel cane*. Summa, Italia, v.16, n.1, p.7-18, 1999.

RAISER, A.G. Reparação do tendão calcaneal em cães. *Ciência Rural*, Santa Maria, v.31, n.2, p.351-359, 2001.

SLATTER, D. *Manual de cirurgia de pequenos animais*. 3. ed. São Paulo: Manole, 2009, 2v, p.2358-2373.

SCHULZ, K.S. Gerenciamento de Lesão ou Doença do músculo e tendão. In: FOSSUM, T.W. *Cirurgia de pequenos animais*. São Paulo: Elsevier, 2014. p.1375-1382.

TOBIAS, K.M.; JOHNSTON, S.A. *Veterinary surgery small animal*. v1. St. Louis: Elsevier. 2011.p.1131