



Original Articles

## Occurrence of oral cavity neoplasms in canines attended at the oncology service of the Federal Rural University of Rio de Janeiro (2011 to 2017)

Ocorrência de neoplasias em cavidade oral em caninos atendidos no serviço de oncologia da Universidade Federal Rural do Rio de Janeiro (2011 a 2017)

Michel Alves da Silva<sup>1</sup> , Felipe Noletto de Paiva<sup>2\*</sup> , Dayane Caicó Collares Araujo<sup>2</sup> , Thiago Souza Costa<sup>2</sup> , Simone Carvalho dos Santos Cunha<sup>3</sup> , Julio Israel Fernandes<sup>2</sup> 

<sup>1</sup> Universidade Federal de São João del Rei

<sup>2</sup> Universidade Federal Rural do Rio de Janeiro

<sup>3</sup> Oncopet Veterinária

### ARTICLE INFO

*Article history*

Received 30 April 2020

Accepted 17 June 2020

*Keywords:*

Neoplasms

Diagnosis

Occurrence

Melanocytic neoplasia

### ABSTRACT

The oral cavity is among the main sites of neoplasia, both benign and malignant. Those with characteristics of malignancy have an unfavorable prognosis due to their biological behavior and diagnostic and therapeutic difficulties. Epidemiological data are important to profile the affected population and establish an early treatment strategy, optimizing treatment and increasing the chances of cure and quality of life. The objective of this study was to present the clinical epidemiological aspects of dogs treated with neoplasms in the oral cavity at the Oncology Service of the Veterinary Hospital of the Federal Rural University of Rio de Janeiro between the years 2011 and 2017 through a retrospective study of all the medical records of the respective service. The epidemiological data extracted from the archives showed that out of 2832 cases of neoplasms treated in the oncology sector over a 7-year interval (2011 to 2017), 176 animals (6.21%) were affected by oral cavity neoplasms. The dogs without a defined breed were the most affected, the main site affected was the maxilla and melanoma was the most prevalent neoplasm.

### RESUMO

A cavidade oral figura entre os principais sítios de acometimento por neoplasias, tanto benignas quanto malignas. Aquelas que possuem características de malignidade têm o prognóstico desfavorável pelo seu comportamento biológico e pela dificuldade diagnóstica e terapêutica. Os dados epidemiológicos são importantes para se traçar um perfil da população acometida e estabelecer uma estratégia de tratamento precoce otimizando o tratamento e aumentando as chances de cura e a qualidade de vida. O objetivo deste trabalho foi apresentar os aspectos clínicos epidemiológicos dos cães atendidos com neoplasias na cavidade oral no Serviço de Oncologia do Hospital Veterinário da Universidade Federal Rural do Rio de Janeiro entre os anos de 2011 e 2017 por meio de um estudo retrospectivo de todos os prontuários do referido serviço. Os dados epidemiológicos extraídos dos arquivos evidenciaram que dos 2832 casos de neoplasias atendidos no setor de oncologia em um intervalo de 7 anos (2011 a 2017), as neoplasias da cavidade oral acometeram 176 animais (6,21%). Os cães sem raça definida foram os mais acometidos, o principal local acometido foi a maxila e o melanoma foi a neoplasia mais prevalente.

*Palavras-chave:*

Neoplasmas

Diagnóstico

Ocorrência

Neoplasia melanocítica

\* Corresponding author: [n-paiva@hotmail.com](mailto:n-paiva@hotmail.com)

## INTRODUCTION

The oral cavity is a common place for a great variety of benign and malignant proliferations, and it is the fourth most common anatomical region for the emergence of neoforations, which represent 6% of all the tumors in dogs (LIPTAK, WITHROW, 2012). Its classification is consensual according to biological behavior and origin (RODRÍGUES-QUIRÓS et al., 1998). Oral cavity tumors can present a huge variety of histological types that are related to their origin tissues (LIPTAK, WITHROW, 2007; WHITE, 2003). Nonodontogenic tumors arise from the structures of the oral cavity, except dental tissues (GOMES et al., 2009), while odontogenic tumors are those that originate from dental structures (RODRÍGUES-QUIRÓS et al., 1998).

The etiology of these tumors, except the viral papillomatosis, remains unknown, although the contribution of some predisposing factors to their appearance is known, as the cited chronic inflammations (CAMARGO, CONCEIÇÃO, COSTA, 2008; RODRÍGUES-QUIRÓS et al., 1998). The most frequently affected sites in the oral cavity are: gum, tongue, labial mucosa, oral mucosa, tonsils, dental alveoli, and soft and hard palate (CAMARGO; CONCEIÇÃO, COSTA, 2008; GOMES et al., 2009; RODRÍGUES-QUIRÓS et al., 1998; WHITE, 2003).

Regarding behavior, benign tumors generally have slow and compressive growth, are capsule-type, do not promote systemic dissemination, in some situations are pedunculated and are potentially easier to remove (LIPTAK, WITHROW, 2007). Malignant tumors are more aggressive as they grow rapidly, invade surrounding tissues, may be ulcerated, hemorrhagic, infected or necrotic, vary in consistency depending on the tissues that constitute it, and may range from friable to hard, and when invasive develop peripheral lymphadenopathy (CATCHPOLE et al., 2003; GRIMES et al., 2017) and metastases, especially for lymph nodes (RODRÍGUES-QUIRÓS et al., 1998).

The scarcity of epidemiological studies of neoplasms in animals in Brazil deprives the knowledge on incidence, recurrence and lethality, restricting the diagnostic, clinical and therapeutic advances. Therefore, this study on neoplasms affecting the oral cavity of dogs treated between 2011 and 2017 at the Veterinary Hospital of the

Federal Rural University of Rio de Janeiro aimed to complement epidemiological information on oral neoplasms in dogs.

## MATERIAL AND METHODS

The study was proved by the Chamber of Ethics in Animal Experimentation (CEUA) with protocol 074/2014.

For the epidemiological study, all the records of the Veterinary Oncology Service (SOV – *Serviço de Oncologia Veterinária*) archive of the Veterinary Hospital (VH) of the Federal Rural University of Rio de Janeiro were highlighted and evaluated between 2011 and 2017, and all dogs that presented some neoforation in the oral cavity were selected. The animals had their clinical data recorded, and general data were collected on sex, breed and place of involvement in the oral cavity. In cases where the diagnosis was obtained, it was performed through cytopathology and histopathology tests.

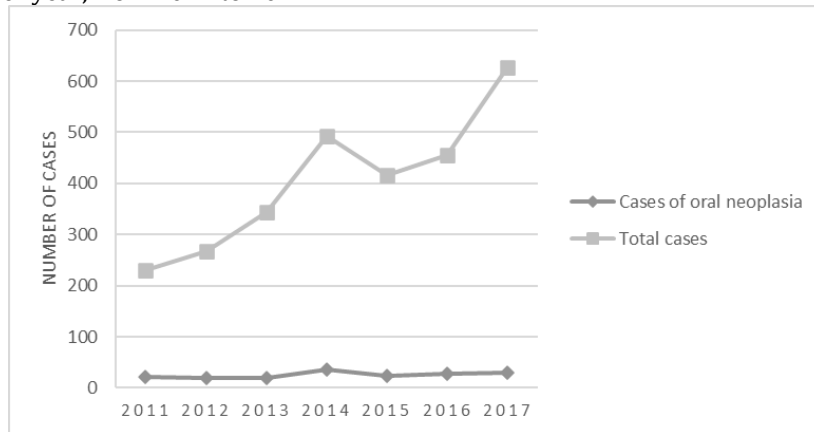
Animals with incomplete records, i.e. with some uninformed epidemiological data, were not considered. Only the initial assistances, adding each animal only once, were considered, disregarding the returns for accompaniment and therapy.

## RESULTS AND DISCUSSION

A total of 2,832 cases of neoplasms were evaluated at the Oncology Service of the Federal Rural University of Rio de Janeiro over a 7-year period, from 2011 to 2017. Of these, 6.21% (176 animals) were treated with a complaint of neoplasia located in the oral cavity.

In 2011, 231 oncologic cases were attended, 22 (9.52%) of which were oral neoplasms; in 2012, there were 268 oncologic cases with 19 oral neoplasms (7.08%); in 2013, there were 343 oncologic cases with 19 oral neoplasms (5.53%); in 2014, there were 493 oncologic cases with 36 oral neoplasms (7.30%); In 2015, 416 oncologic cases with 23 oral neoplasms (5.52%) were treated; in 2016, 455 oncologic cases with 27 oral neoplasms (5.93%) were treated; and in 2017, 626 cases were treated, of which 30 were oral neoplasms (4.79%), as shown in Figure 1.

Figure 1. Number of animals treated at the Veterinary Oncology Service – Veterinary Hospital – Universidade Federal Rural do Rio de Janeiro per year, from 2011 to 2017.



The number of cases of dogs with neoplasms in the oral cavity per year showed a small variation between the years 2011 and 2017, with a median value of 23 cases (19 - 36), while the total number of cases attended in the sector showed a continuous increase, ranging from 231 cases in 2011 to 626 cases in 2017, with a median of 416 cases. The Shapiro-Wilk normality test was conducted to verify the null hypothesis that the data would have been sampled from a normal distribution (TAYLOR, JOHN, 2011). As the data did not deviate from the Gaussian distribution ( $p=0.4068$ ), they were analyzed by the independent t test. All tests were performed with a significance level of 0.05. Therefore, the best measures of location and dispersion to evaluate the number of cases of dogs with neoplasms in the oral cavity per year would be the mean  $\pm$  standard deviation ( $25.14 \pm 6.26$ ), while for total neoplasms  $404.6 \pm 136.7$ . This increase of the casuistry is due to the expansion of the residency program in Veterinary Medicine in the Veterinary Hospital, which allowed a larger number of animals to be assisted per day and this increase in the total of cases associated to a stabilization of the cases of oral neoplasia led to a progressive decrease of the relative proportion, diminishing from 9.52% to 4.79% of the cases per year of assistance. A Pearson correlation test was performed to check whether there was an association between increased general neoplasia cases and increased oral neoplasia cases. It can be observed that this correlation is positive ( $\rho=0.847$ ;  $p=0.025$ ) and significant, demonstrating that the increase in the cases of attendance carried through for the expansion of the residency program in Veterinary Medicine in the Veterinary Hospital also resulted in an increase in the diagnosis of oral neoplasia.

In a study conducted by Gomes and collaborators (2009), in which an epidemiological evaluation of dogs attended at the Veterinary Hospital of the Federal University of Rio Grande do Sul (UFRGS) was performed, only 79 dogs manifested neoplasms in the oral cavity over a period of 4 years. In another study, Kimura, Gárate and Dagli (2012) evaluated 1,813 cases of canine neoplasms in the animal pathology service of the School of Veterinary Medicine of the University of São Paulo (USP) between 1993 and 2002 (10 years). Of these, approximately 2%

were related to the oral cavity. The incidence of neoplasms from this location is lower in the studies than observed in the present study. The greatest value observed in the study may be related to the distribution of sectors and services in the hospital where such work is performed, in which many times neoplasms in specific systems, such as ocular, cardiac and cutaneous can be treated in the ophthalmology, cardiology and dermatology sectors; however, in the absence of a dentistry sector, all oral neoplasms are treated by the oncology sector.

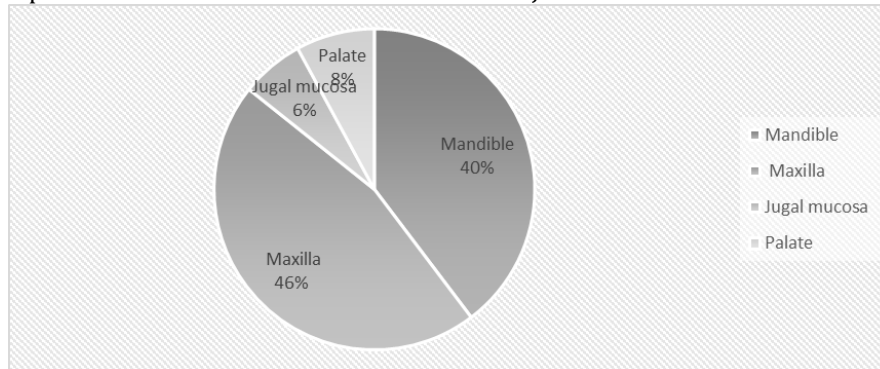
Among the total number of animals affected, most were regarded as having an undefined breed (UDB) (38.64%), followed by the breeds: Poodle (14.20%), Cocker Spaniel (9.09%), Rotweiler (6.25%), Pinscher (5.11%), Labrador (3.98%), Chow Chow (3.41%), Dachshund (3.41%), with the other breeds adding smaller percentages, associated in a single group (15.91%). Gomes et al. (2009) and Teixeira (2010) report a similar prevalence, contrary to the work performed by Ramos-Vara et al. (2000), which brings discordant prevalence related to the races most present in those countries. Gomes and collaborators (2009) conducted a similar study with dogs treated at the UFRGS Veterinary Hospital, observing a higher prevalence in UDB and Poodle animals, as in this study. The needy/lower purchasing power population represents the largest portion of owners seeking care for their animals in the hospital where the work is carried out, and there is also a great demand for rescue groups of animals in vulnerable conditions. These groups generally have animals of undefined or mixed breed from crossing of different breeds that lose their breed standard.

Regarding sex, 52.84% of the animals were male, and 47.16% were female. The distribution remained very close to being equivalent between the sexes as in the work of Gomes et al. (2009). A frequency comparison between males and females was performed by the chi-square test of a variable and it was observed that the observed frequencies did not differ from those expected for different sexes ( $\chi^2=0.568$ ;  $p=0.451$ ).

The last factor evaluated was the location of the neoplasms in the oral cavity. The affected regions were divided into four groups: mandible, maxilla, palate, and jugal mucosa. The region with the greatest involvement was the maxilla (46.03%), followed by the mandible

(39.68%), palate (7.94%), and jugal mucosa (6.35%) (Figure 2). The maxilla and mandible were the most affected sites, as described in the literature (TODOROFF, BRODEY, 1979).

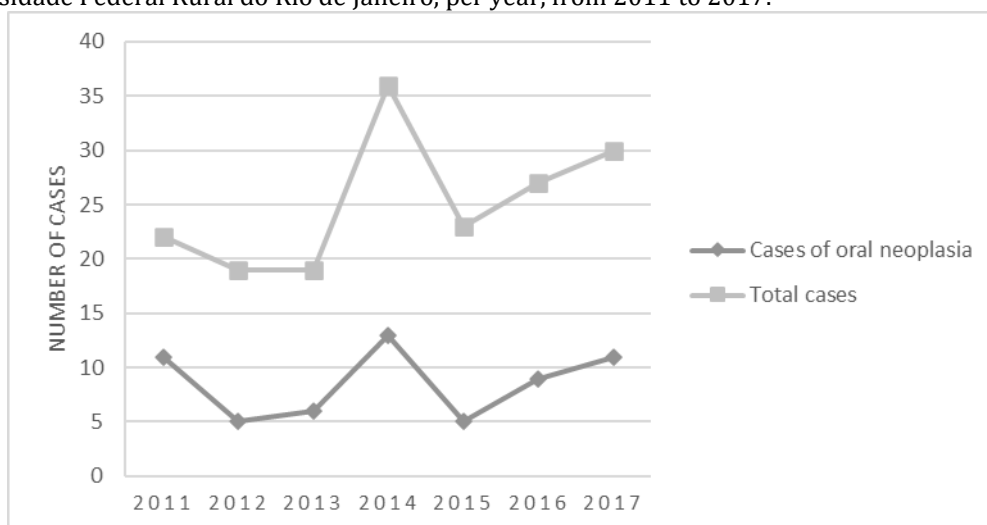
Figure 2. Percentage of location of the lesions in dogs affected by oral neoplasms treated in the Veterinary Oncology Service - Veterinary Hospital - Universidade Federal Rural do Rio de Janeiro.



The most diagnosed neoplasm was oral melanoma, with a total of 60 cases, representing 34.09% of the cases of oral cavity neoplasms, and 2.11% of the total neoplasms assisted in the oncology service (figure 3). The relative frequency was higher than described by Ramos-Vara et al. (2000), where the prevalence of oral melanoma was

0.99% of the cases analyzed. The authors highlight that melanoma was the main neoplasm that affected the oral cavity as well as the publications of Stopiglia et al. (1992), Requicha et al. (2010) and contrary to that reported by Todoroff, Brodey (1979), and Guerra et al. (1989).

Figure 3. Number of animals diagnosed with oral melanoma treated at the Veterinary Oncology Service - Veterinary Hospital - Universidade Federal Rural do Rio de Janeiro, per year, from 2011 to 2017.



## CONCLUSIONS

The most common oral neoplasia was oral melanoma. The animals with Undefined Breed were those with higher prevalence, a factor that may be related to the public attended by the veterinary hospital. The maxilla was the site most affected by oral cavity neoplasms.

## REFERENCES

ARNOLD, T. B.; EMERSON, J. W. Nonparametric Goodness-of-Fit Tests for Discrete Null Distributions. *The R Journal*, v.3, n. 2, p. 34-39, 2011.

CAMARGO, L. P.; CONCEIÇÃO, L. G.; COSTA, P. R. D. S. Neoplasias melanocíticas cutâneas em cães: estudo retrospectivo de 68 casos

(1996-2004). *Brazilian Journal Veterinary Research Animal Science*, v. 45, n. 2, p. 138-152, 2008.

CATCHPOLE, B. et al. Development of a multiple-marker polymerase chain reaction assay for detection of metastatic melanoma in lymph node aspirates of dogs. *American Journal of Veterinary Research*, v. 64, n. 5, p. 544-549, 2003.

GOMES, C. et al. Avaliação epidemiológica de cães com neoplasias orais atendidos no hospital de clínicas veterinárias da Universidade Federal do Rio Grande do Sul. *Ciência Animal Brasileira*, v. 10, n. 3, p. 835-839, 2009.

GRIMES, J. A. et al. Agreement Between Cytology and Histopathology for Regional Lymph Node Metastasis in Dogs With Melanocytic Neoplasms. *Veterinary Pathology*, p. 3, n. 27, 2017.

GUERRA, J. L. et al. A retrospective study of oral neoplasms in dogs: a survey from 1941 to 1986. *Revista da Faculdade de Medicina Veterinária e Zootecnia da Universidade de São Paulo*, v. 26, n. 2, p. 207-212, 1989.

KIMURA, K. C.; GÁRATE, A.P.; DAGLI, M. L. Z. Retrospective study of Neoplasms in Domestic Animals: a Survey Between 1993 and 2002 of the Service of Animal Pathology, Department of Pathology, School of Veterinary Medicine and Animal Science, University of São Paulo, Southeast Brazil. *Brazilian Journal of Veterinary Pathology*, v. 5, n. 2, p. 60 - 69. 2012

LIPTAK, J. M.; WITHROW, S. J. Cancer of the Gastrointestinal Tract. In: WITHROW, S. J.; VAIL, D. M. *Withrow and MacEwen's Small Animal Clinical Oncology*. 5 ed. St. Louis: Elsevier - Saunders, 2012. p. 381-431.

RAMOS-VARA, J. A., et al. Retrospective study of 338 canine oral melanomas with clinical, histologic, and immunohistochemical review of 129 cases. *Veterinary Pathology*, v. 37, n. 6, p. 597-608, 2000.

REQUICHA, J. F. et al. Neoplasias Da Cavidade Oral Do Cão: Uma Revisão. *Revista Brasileira de Medicina Veterinária*, v. 37, n. 1, p. 22-30, 2015.

RODRÍGUEZ-QUIROS, J. et al. Neoplasias orais em pequenos animais - cirurgia maxilofacial I. In: SAN ROMÁN, F. *Atlas de Odontologia de Pequenos Animais*. São Paulo: Editora Manole S.A., 1999. p 143-163.

STOPIGLIA, A. J. et al. Estudo clínico e anátomo-patológico das formações neoplásicas e não neoplásicas da cavidade bucal de cães. *Comunicações Científicas da Faculdade de Medicina Veterinária e Zootecnia da USP*, v. 16, n. 1/2, p. 33-39, 1992.

SCOTT, D. W.; MILLER, W. H.; GRIFFIN, C. E. Structure and Function of the Skin. In: SCOTT, D. W.; MILLER, W. H.; GRIFFIN, C. E. *Muller & Kirk's Small Animal Dermatology*. 6th. ed. Philadelphia: Elsevier, 2001, p. 1-70.

SMITH, S. H.; GOLDSCHMIDT, M. H.; MCMANUS, P. M. A Comparative Review of Melanocytic Neoplasms. *Veterinary Pathology*, v. 39, n. 6, p. 651-678, 2002.

TEIXEIRA, T. F. Retrospective study of melanocytic neoplasms in dogs and cats. *Brazilian Journal of Veterinary Pathology*, v. 3, n. 2, p. 100-104, 2010.

TODOROFF, R. J.; BRODEY, R. S. Oral and pharyngeal neoplasia in the dog: a retrospective survey of 361 cases. *Journal American Veterinary Medical Association*, v. 175, n. 6, p. 567-571, 1979.

WHITE, R. A. S. Mast cell tumors. In: DOBSON, J. M.; LASCELLES, B. D. X. *BSAVA: manual of canine and feline oncology*. Gloucester: BSAVA. p. 161-167. 2003.