



Original Articles

Evaluation of teaser buffaloes subjected to surgical technique for fixation of the caudal curvature of the sigmoid flexure with myectomy of the penis retractor muscle

Avaliação de rufiões bubalinos submetidos à técnica cirúrgica de fixação da curvatura caudal da flexura sigmóide com miectomia do músculo retrator do pênis

Thais Bastos Rocha¹ , Diego Moraes Soares¹ , Wendel Adelino Policarpo¹ , Rafael Rodrigues Soares¹ , Kaio Barros Bezerra² , Fábio Henrique Evangelista de Andrade³ , Solange de Araújo Melo³ , Helder de Moraes Pereira⁴ 

¹ Programa de Pós-Graduação em Ciência Animal, Universidade Estadual do Maranhão, São Luís, Maranhão, Brasil

² Msc. Médico Veterinário Autônomo, Maranhão, Brasil

³ Departamento de Patologia, Universidade Estadual do Maranhão, São Luís, Maranhão, Brasil

⁴ Departamento das Clínicas, Universidade Estadual do Maranhão, São Luís, Maranhão, Brasil

ARTICLE INFO

Article history

Received 18 February 2020

Accepted 02 April 2020

Keywords:

Surgery

Ruminant

Teaser

Palavras-chave:

Cirurgia

Ruminante

Rufião

ABSTRACT

The objective of this work was to evaluate the efficiency technique of fixation of the caudal curvature of the sigmoid flexure with myectomy of the penis retractor muscle and the performance of teaser bulls after surgery, through the detection of females in estrus, without performing the copulation. 12 teaser buffaloes were used without defined breed, with an average age of 20 months, weighing on average 200 kg. The animals were subjected to food and water fasting for 12 hours to provide tranquilization in advance. The surgical procedure consisted of the exteriorization of the sigmoid flexure, myectomy of penis retractor muscle and fixation of the caudal curvature of the penis sigmoid flexure. Of the 12 evaluated teaser buffaloes in the libido test, 100% performed the flehmen reflex, mount attempt, incomplete and complete jump with total inability of the penis exposure. It was concluded that this technique can be used safely, having simplicity in its execution, effective results and mainly low cost, not interfering in the animals' libido. The animals when tested as teaser buffaloes kept the libido during the experimental period with total inability of exposure of the penis.

RESUMO

O objetivo do presente trabalho foi avaliar a técnica de fixação da curvatura caudal da flexura sigmóide com miectomia do músculo retrator do pênis e o desempenho de rufiões bubalinos após cirurgia, através da detecção de fêmeas em estro, sem executar a cópula. Foram utilizados 12 bubalinos sem raça definida, com idade média de 20 meses, pesando em média 200 kg. Os animais foram submetidos a jejum alimentar e hídrico de 12 horas para tranquilização prévia. O procedimento cirúrgico constou na exteriorização da flexura sigmóide, miectomia do músculo retrator do pênis e fixação da curvatura caudal da flexura sigmóide do pênis. Dos 12 rufiões avaliados no teste de libido, 100% realizaram reflexo de flehmen, tentativa de monta, salto incompleto e completo com total incapacidade de exposição do pênis. Conclui-se que esta técnica pode ser utilizada com segurança, apresentando simplicidade na sua execução, eficácia nos resultados e principalmente baixo custo, não interferindo na libido dos animais. Os animais quando testados como rufiões mantiveram a libido durante o período experimental com total incapacidade de exposição do pênis.

INTRODUCTION

The teaser buffaloes were introduced in Brazil from the end of the 19th century, in small batches originating

* Corresponding author: helderpereirap@yahoo.com.br

from Asia, Europe (Italy) and the Caribbean, motivated more by their exoticism than for their zootechnical qualities. Their adaptation to the most varied environments, high fertility and longevity productive, allowed the flock had a significant evolution, and no more than 200 animals introduced in the country, resulted in a flock of 495 thousand buffaloes in 1980 (BERNARDES, 2007).

The zootechnical interest the growth of the buffalo herd must be linked to the control of the productivity, which enables the identification of individuals who have genetic merit and, consequently, the multiplication and distribution of livestock breeders, which is possible only with the aid of the reproduction biotechnologies. In this context, the artificial insemination (AI), which allows the multiplication of genetic material of paternal origin, is indispensable for the species improvement (BARUSELLI; CARVALHO, 2006).

The sazonalidade of the reproduction of buffaloes in each region is a characteristic to be considered on the implementation of a reproductive program. This species suffers strong influences of photoperiod and demonstrates direct relationship with the proximity to equator line (latitude) and the seasons of the year. In South and Southeast of Brazil the reproductive activity usually occurs between February and April. In medium Amazonas and Para the buffaloes behave as continuous polyestrous. In Maranhao, it varies between January and July, with highest occurrence in May (TORRES-JÚNIOR et al., 2016).

A fact which makes the IA process difficult, in function of the need to maintain in the property at least two teasers, one in the pasture for the estrus detection and another in the corral for detection of the end of the estrus (OHASHI et al., 2006).

In the teasers preparation one must seek techniques that avoid the practice of coitus (BEZERRA et al., 2007). Some techniques used allow copulation, as vasectomy (THARP, 1955) and the removal of the tail of the epididymis (WILTBANK, 1961; OHEME, 1968), allowing the transmission of diseases such as trichomoniasis. Other interventions such as the penis amputation (STRAUB; KENDRICK, 1965), lateral deviation of the penis (ARBEITER et al., 1965; WEISSENBERG; COHEN, 1971; ROYES; BIVIN, 1973); fixation of the penis in the ventromedial wall of the abdomen (BARUSELLI et al., 1999), and the stenosis of the preputial ostium (CASTRO et al., 1988), may prevent the copulation, but determine decreased identification of females in estrus (ALVARENGA, 1976).

The techniques described above have disadvantages in return of the animal to the service, as well as complicated post-operative period. Canabrava et al. (2000) upon evaluating the influence of antimicrobial prophylaxis in the rate of postoperative infection, in the surgery of the penis fixation to the ventro-abdominal wall in cattle, observed discrete and transitory edema

and that at the end of the study, the prophylactic administration of antibiotics showed no benefits.

Silva et al. (2000) studied the complications resulting from the modification of the technique of adhesion of the penis to the abdominal wall. These authors concluded that in the postoperative period these animals presented rupture of the urethra, partial and total dehiscence of the wound, tissue necrosis and subcutaneous abscesses.

Pereira et al. (2003), while studying the preparation of teaser goats using the technique proposed in this study, concluded that the goats subjected to this surgical procedure remained the libido during the experimental period, showing total inability of exposure of the penis, not subjecting the risk of fertilization and/or sexually transmitted infections. They also stated that this technique can be safely performed in the field, due to its simplicity in its implementation and efficiency in the results. Feitosa et al. (2006) and Oliveira et al. (2007), studying the preparation of teasers in sheep and cattle, respectively, using the same technique, obtained similar results.

Thus, the objective of this work was to evaluate the fixation technique of fixation of the caudal curvature of the sigmoid flexure with myectomy of the penis retractor muscle and the performance of teaser bulls after surgery, through the detection of females in estrus, without performing the copulation.

MATERIAL AND METHODS

This study was approved by the Committee on Ethics and Animal Experimentation (CEEA/CVMP/UEMA), according to process no. 17/2017, approved on 24/11/2017.

12 male teaser buffaloes, whole, without defined breed (SRD) were used, at the age of 20 months, with an average weight 200 kg, good body score and absence of physical defects that could impair the performance as a teaser. These animals were subjected to an individual clinical examination, according to Rosenberg (1997), with special emphasis on the reproductive system.

For the choice of these animals a simple libido test was conducted, which consisted in the observation of mounts, before a female in estrus. The animals were subjected to a libido test with time determined (thirty minutes) for assessment of sexual behavior before surgery and in the post-surgery. For this evaluation the estrus was induced in three female buffaloes, which received treatment on the basis of GnRH and prostaglandin according to the protocol: day 0, application of 1 ml of GnRH; day 7, application of 2 ml of prostaglandin; day 9, application of 1 ml of GnRH; day 10, observation of estrus.

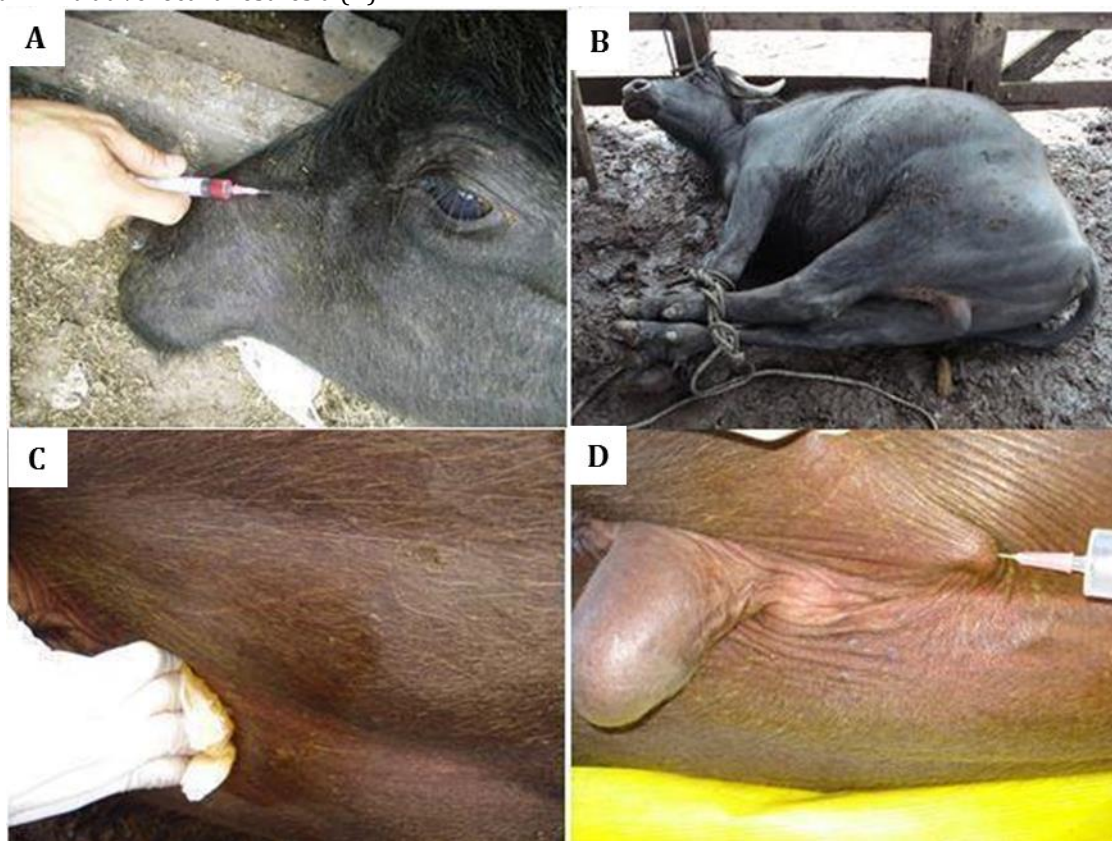
The assessment of sexual behavior was performed individually, for thirty minutes, in closed corral, verifying the intensity of sexual interest demonstrated by each assessed buffalo (BASCUNÁN et al., 2008). In addition to sexual behavior the ability of exposure or not of the

penis of these teaser buffaloes was assessed. All the procedures were performed at AGROPAN Farm, municipality of Arari-Ma, as well as the post-operative monitoring and assessment of the teaser buffaloes' performance.

These animals were subjected to food and water fasting for 12 hours, then reassured with xylazine hydrochloride in the dose of 0.05 mg/kg intravenously (figure 1A). 20 minutes after the tranquilization, the teaser buffaloes

were positioned in the right lateral decubitus position (figure 1B), for subsequent trichotomy and antisepsis with alcohol-iodine 2% in the median line in the perineal region of the caudal face of the base of the scrotum (figure 1C). The anesthesia used was infiltrative local with subcutaneous lidocaine hydrochloride 2% with vasoconstrictor, at a dose of 9 mg/kg of body weight in the location of the incision (figure 1D). For the surgeries, routine diuresis, hemostasis, synthesis and auxiliary material were used.

Figure 1. Pictures of a teaser buffalo subjected to tranquilization with xylazine hydrochloride (A), in the right lateral decubitus position being prepared for the surgical procedure (B), antisepsis of the surgical field (C), and anesthetic protocol with infiltrative local anesthesia (D).



The surgical procedure was originally carried out with skin incision in the craniocaudal direction, in the perineal median line (figure 2A). The cutaneous, subcutaneous tissues and the muscles were incised until location of the sigmoid flexure of the penis (figure 2B), this was exteriorized and tractioned caudally, separating the glans from the ostio prepuical. The retractor penis muscles were divulsed (figure 2C), and then the myectomy entire was performed with blunt tip scissors (figure 2D).

The tunica albuginea of the lateral face of the penis was scarified with scalpel (figure 3A). The lateral face of the cavernous body received four stitches with simple interrupted suture with 0.40 sterilized common nylon wires (figure 3B). The reduction of subcutaneous spaces was performed with simple continuous stitches and then the Wolff skin suture in "U" was made (figure 3C). The

treatment consisted of topical application of tar-based healing substances, black smoke and toluol (friezol unguento®), once a day for eight days (figure 3D). Parenteral antibiotic therapy with G procaine penicillin, potassium and benzathine was administered and associated with erythromycin (Megacilin®) in the dosage of 32000 IU/kg of live weight, by intramuscular for three days every 24 hours (figure 3). The withdrawal of the stiches was performed ten days after the surgery.

The ability of penis exposure and sexual behavior (Flehmen reflex, mount attempt, incomplete and complete jump) of these teaser buffaloes were evaluated 30 days after the surgical procedure by means of the libido test in corral, then after being selected, the animals were placed into service for a period of ninety days in the field.

Figure 2. Pictures of a teaser buffalo where it is possible to observe the beginning of surgery with the skin incision in the perineal median line (A), exteriorization of the sigmoid flexure of the penis (arrow) (B), exteriorization of the caudal portion of the sigmoid flexure and tractioning of the penis retractor muscles (arrow) (C) and total myectomy of the penis retractor muscles (D).

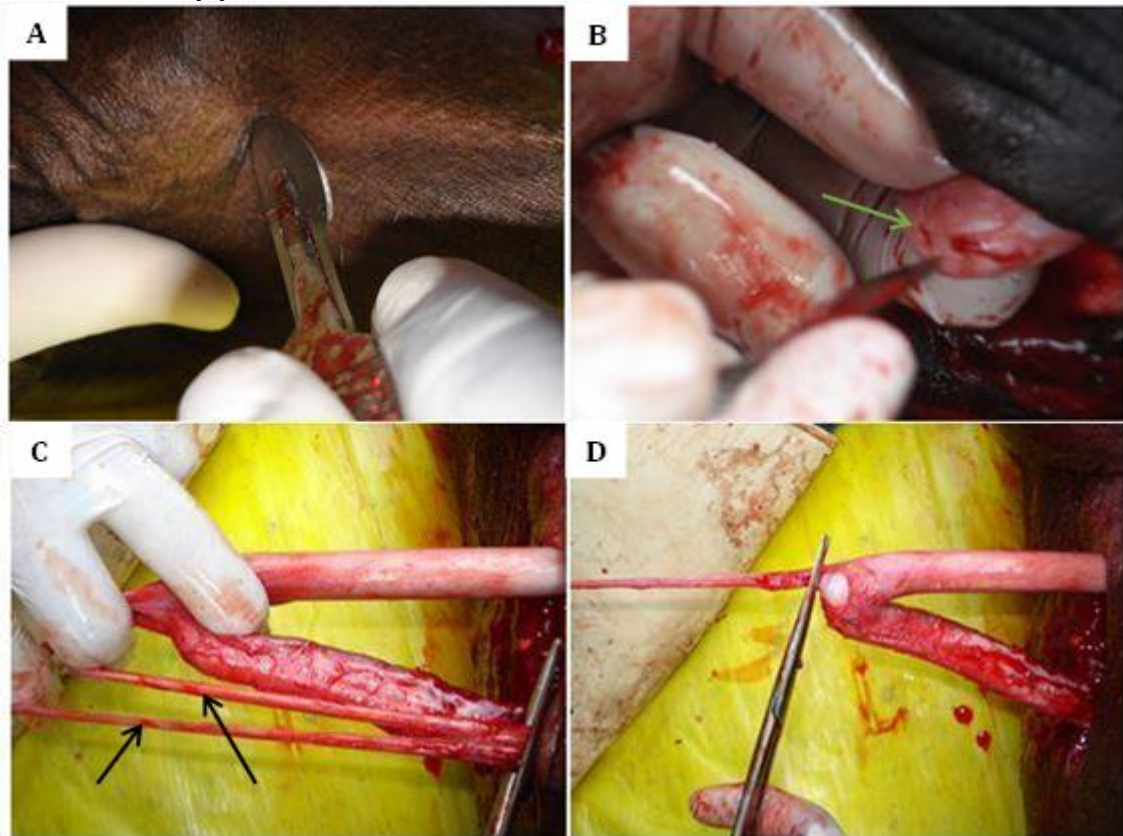
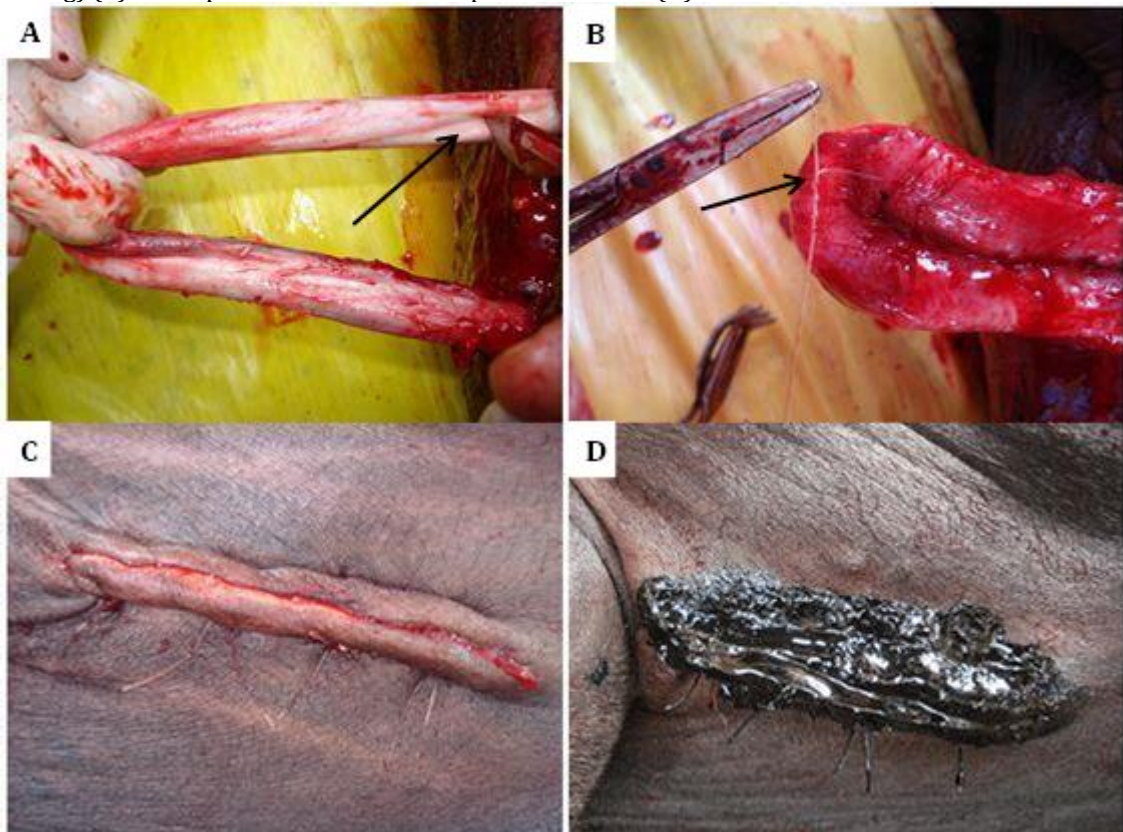


Figure 3. Pictures of a teaser buffalo, evidencing the scarification of the caudal portion of the sigmoid flexure of the penis (arrow) (A), fixation of the sigmoid flexure of the penis with simple separated stitches (arrow) (B), Wolff skin suture (dehorning) (C) and topical treatment of the operative wound (D).



RESULTS AND DISCUSSION

It was identified that the food and water fasting for 12 hours were enough to prevent bloat and urination during the surgical procedure. There is no consensus in the literature regarding the period of fasting to be used, being more common the food and water fasting for 24 hours (WILTBANK, 1961; EURIDES et al., 1992; SILVA JÚNIOR et al., 1998) or 12 hours (POMPERMAYER et al., 1993; EURIDES et al., 1998). Similar results were described by Feitosa et al. (2006) using the 24-hour fasting and water fasting for 12 hours in sheep.

The pre-medication with xylazine hydrochloride and infiltrative local anesthesia, produced enough analgesia and muscle relaxation, allowing a improving in the lateral decubitus, facilitating the surgical procedure. Similar reports were described by Pinilla De Leon et al. (1996), Eurides et al. (1998), Pereira et al. (2003) in goats, Feitosa et al. (2006) in ovine and Bezerra et al. (2007) in cattle.

The surgical technique was successfully performed, being a little bloody technique. The free end of the penis remained distant from the preputial ostium due to retraction of the sigmoid flexure and the myectomy of the retractor muscle, preventing the action of this at the time of erection. Eurides; Pipi (1983) were the first to perform the caudal curvature fixation of the sigmoid flexure of the penis in cattle. The technique was later used in goats (POMPERMAYER et al., 1993; PEREIRA et al., 2003), in sheep (EURIDES et al., 1998; FEITOSA et al.,

2006; TEIXEIRA et al., 2013) with good results. According to the authors above, the animals subjected to fixation of sigmoid flexure without removing the retractor muscles demonstrated discomfort during the copulation. It differs from the results of this research once the teaser buffaloes were subjected to resection of these muscles, not demonstrating discomfort and, consequently, keeping the libido and satisfied sexual behavior, which contributed to a greater use of the teaser buffalo in the field. The scarification of the tunica albuginea facilitated the adhesion between the ends of the caudal curvature of the sigmoid flexure, as well as the suture technique in the lateral face of the penis cavernous body reduced the risk of accident in the urethra, corroborating with the findings of Pinilla De Leon et al. (1996), Pereira et al. (2003) in goats, Feitosa et al. (2006), in ovine and Bezerra et al. (2007), in cattle. In the postoperative period there were no changes arising from the surgery, and the teaser buffaloes during the period of service in the field, showed total inability of exposure of the penis. Similar results were described by Pereira et al. (2003) in goats, Feitosa et al. (2006) in ovine and Bezerra et al. (2007) in cattle.

Of the twelve teaser buffaloes evaluated in the libid test in the field, 100% performed approximation of the female in the estrus (figure 4A), smelling the genitalia (figure 4B), preparing to jump performing the jump (figure 4C e 4D 4) (tabela 1). The same results were described by Bezerra et al. (2007) in cattle.

Table 1. Performance of buffaloes in a test of libido in closed corral with determined time, after being turned into teasers.

Animals	Note	Classification	Time
1	9	Excelent	30 minutes
2	10	Excelent	30 minutes
3	7	Good	30 minutes
4	8	Very good	30 minutes
5	9	Excelent	30 minutes
6	7	Good	30 minutes
7	7	Good	30 minutes
8	9	Excelent	30 minutes
9	10	Excelent	30 minutes
10	8	Very good	30 minutes
11	9	Excelentt	30 minutes
12	8	Very good	30 minutes

< 5 (very weak), 5 - 6,9 (weak), 7 - 7,9 (good), 8 - 9 (very good), 9 - 10 (excelent)

They also performed reflex of flehmen, mounting attempt, incomplete and complete jump with total inability of the penis exposure (figure 5), differing from other techniques where it is necessary to suture the penis to the ventral wall of the abdomen or perineal region promoting pain every time that the animal tries to expose the penis, and as time

goes by the teaser bull loses the libido by associating the mounting to pain (MARTINS; SILVA, 2012). Thus, the result of this technique is similar to that described by Bezerra et al. (2007), that proposed the association of myectomy technique of penis retractor muscle to penile fixation, obtaining greater time of use of the teaser bull in the field.

Figure 4. Pictures of the teaser buffaloes in service, where it is possible to observe the approximation of the teaser (A), smelling the female genitalia (B), preparing for the mount (C), and performing the jump (D).





Figure 5. Pictures denoting the teaser buffaloes in service, where the Flehmen reflex (A), mounting attempt (B), incomplete jump (C) and complete jump with total inability of the penis exposure (D).



CONCLUSIONS

The buffaloes subjected to this surgical procedure when used as teasers kept the libido during the experimental period, demonstrating total inability of the penis exposure and maintenance of sexual behavior. The technique of curvature fixation of the sigmoid flexure with myectomy of the penis retractor muscle, can be

used safely in the field, due to its simplicity in its implementation and efficiency in the results.

REFERENCES

ALVARENGA, J. Preparação de rufões bovinos. *Atualidades Veterinárias*, v. 5, p. 4-10, 1976.

- ARBEITER, K. et al. Surgical displacement of the bull's penis. Sterile copulation for the stimulation of oestrus and ovulation in cow. *Wieu Tieranztl Mschr*, v. 52, p. 765-773, 1965.
- BARUSELLI, P. S. et al. Preparo de rufiões pela fixação do corpo do pênis na parede ventro-medial do abdome. *Revista Brasileira Reprodução Animal*, v.23, p. 353-354, 1999.
- BARUSELLI, P. S.; CARVALHO, N. A. T. Manejo reprodutivo da búfala leiteira. *Revista de Ciências Agrárias, Suplemento*. v. 45, p. 1-23, 2006.
- BASCUÑAN, D, S. R.; JORGE, A, M.; ROCHA, G. P.; WESCHLER, F. S.; ANDRIGHETTO, C. Comportamento sexual de touros zebrúinos e angus em central de coleta e processamento de sêmen. *Revista Brasileira de Zootecnia*, v. 37, n. 2, p. 254-260, 2008.
- BERNARDES, O. Bublinocultura no Brasil: situação e importância econômica. *Revista Brasileira de Reprodução Animal*, v. 31, p. 293 – 298, 2007.
- BEZERRA, K. B. et al. Avaliação da técnica cirúrgica de fixação da curvatura caudal da flexura sigmóide e miectomia do músculo retrator do pênis, no preparo de rufiões em bovinos. *Acta Veterinaria Brasílica*, v. 1, p. 130-136, 2007.
- CANABRAVA, H. A. N. et al. Antibiótico profilaxia na cirurgia de fixação do pênis a parede abdominal em bovinos. In: Congresso Brasileiro de Cirurgia e Anestesia Veterinária, 4, Goiânia. Anais... 2000 p. 127.
- CASTRO, E. A. et al. Preparo de rufiões suínos pela técnica do desvio lateral do óstio prepucial. *Revista Brasileira de Reprodução Animal*, v.12, p. 9-15, 1988.
- EURIDES, D. et al. Preparação de rufiões bovinos por remoção do ligamento apical do pênis. *Ciência Rural*, v.22, p. 185-189, 1992.
- EURIDES, D. et al. Preparo de rufiões ovinos por fixação da curvatura caudal da flexura sigmóide do pênis. *Revista Brasileira Ciência Veterinária*, v. 5, p. 59-62, 1998.
- EURIDES, D.; Pippi, L. N. Preparação de rufiões bovinos por fixação da curvatura caudal da flexura sigmóide do pênis. *Ciência Rural*, v. 13, p. 83-93, 1983.
- FEITOSA, M. L. T. et al. Preparo e avaliação da libido em rufiões ovinos através da fixação da curvatura caudal da flexura sigmoide com miectomia do músculo retrator do pênis. *Ciência Animal*, v.16, p. 89-94, 2006.
- MARTINS, E. A. N.; SILVA, L. C. L. C. Manual de preparo de rufiões. 1ª Ed. São Paulo: Med.Vet. 2012. 69p.
- OEHME, F. W.. Resection of the bovine epididymis. A procedure for preparing teaser bulls and securing increased weight gain in male feeder cattle. *Veterinary Medicine Small Animal Clinician*, v. 63, p. 603-606, 1968.
- OHASHI, O. M. et al. Biotecnologia da reprodução aplicada aos bubalinos. *Revista de Ciências agrárias*, v. 45, p. 1-14, 2006.
- PEREIRA, H. M. et al. Rufiação através da fixação da flexura sigmóide e miectomia do músculo retrator do pênis. *Revista Brasileira Reprodução Animal*, v.27, p.493-498, 2003.
- PINILA DE LEON, J. I. et al. Preparação de rufiões caprinos pela fixação da curvatura caudal da flexura sigmóide do pênis. *Ciência Rural*, v.26, p. 241-245, 1996.
- POMPERMAYER, L. G. et al. Preparo de rufiões caprinos pela técnica do transplante do óstio prepucial para a prega inguinal. *Arquivo Brasileiro de Veterinária e Zootecnia*, v. 45, p. 305-313, 1993.
- ROYES, B. A. P.; BIVIN, W. S. Surgical displacement of the pênis in the Bull. *Journal America Veterinary Medicine Association*, v.163, p. 56-7, 1973.
- ROSEMBERG, G. Exame Clínico de Bovinos. 4ª Ed. Guanabara Koogan. Rio de Janeiro. 1997, 419p.
- SILVA, L. A. F da et al. Complicações resultantes da modificação da técnica de aderência do pênis a parede abdominal no preparo de rufiões bovinos. In: IV Congresso Brasileiro de Cirurgia e Anestesia Veterinária. Anais, Goiânia, p. 128, 2000.
- SILVA JÚNIOR, V. J. et al. Preparo de rufiões bovinos pelas técnicas de fixação lateral da curvatura caudal da flexura sigmóide do pênis e da estenose e da lamina interna prepucial com anel de aço de inoxidável. *Ciência Veterinária nos Trópicos*, v.1, p. 11-17, 1998.
- STRAUB, O. C.; KENDRICK, J. W. Preparation of teaser bulls by penectomy. *Journal America Veterinary Medicine Association*, v.147, p. 373-376, 1965.
- THARP, V. L. 1955. Vasectomy in the bull. *Journal America Veterinary Medicine Association*. 126, 194-197.
- TEIXEIRA, P. P. M.; OLIVEIRA, M. E. F.; SILVA, M. A. M.; SANTOS, V. J. C.; RODRIGUES, L. F. S. VICENTE, W. R. R. Técnicas empregadas no preparo de rufiões em ovinos: revisão de literatura. *Revista Brasileira de Reprodução Animal*, v. 37, n. 1, p. 14-22, 2013.
- TORRES-JÚNIOR, J. R.; RIBEIRO, L. dos S.; PEREIRA, H. G.; FRANÇA, I. G. Sazonalidade reprodutiva de bubalinos (*Bubalus bubalis*) em regiões equatorial e temperada. *Revista Brasileira de Reprodução Animal*, v. 40, n. 4, p. 142-147, 2016.
- WEISSENBERG, Y.; COHEN, R. The preparation of teaser bulls by surgical deflection of the penis. *Refuah Veterinary*, v. 28, p. 39-41, 1971.
- WILTBANK, J. N. A technique for sterilization of the bulls. *Southwestern Veterinarian*, v. 14, p. 194-197, 1961.