




Clinical Reports

Black hair follicular dysplasia in a fox paulistinha dog: clinical and histopathological features

Displasia folicular do pelo preto em um cão Fox paulistinha– características clínicas e histopatológicas

Beatriz Crepaldi Aléssio¹ , Daniella de Braga¹ , Mariana I. Poci Palumbo² , Veronica J. Babo-Terra^{2*} 

¹ Médica Veterinária Autônoma.

² Professora de Clínica Médica e Terapêutica de Pequenos Animais, Faculdade de Medicina Veterinária e Zootecnia da UFMS, Campo Grande, MS.

ARTICLE INFO

Article history

Received 11 November 2019

Accepted 21 May 2020

Keywords:

Alopecia
Canine
Dermatopathology
Inherited skin disorder

Palavras-chave:

Alopecia
Cães
Dermatopatologia
Dermatose hereditária

ABSTRACT

Black hair follicular dysplasia (BHFD) is an unusual canine skin disorder defined as alopecia confined to black regions of the hair coat. First clinical abnormalities are usually noted around four weeks of age and comprise fracture of hair shafts in black-coated regions, later resulting in partial alopecia, usually, on the head, ear pinnae, neck, and back, whereas some nonblack-coated areas may exhibit normal hair. The diagnosis is confirmed by histopathologic features. This article aims to report a case of black hair follicular dysplasia in a seven-month-old Fox Paulistinha male dog showing alopecia restricted to black-haired areas, in which diagnosis was confirmed by histopathological exams that showed follicular dysplasia associated with melanic accumulation in the hair shaft and in and deep dermal tissue.

RESUMO

A displasia folicular do cabelo preto (BHFD) é uma doença incomum da pele canina definida como alopecia confinada a regiões de pelo preto. As primeiras anormalidades clínicas são geralmente notadas em torno de quatro semanas de idade e compreendem fratura dos pelos em regiões cobertas de pelagem preta, resultando posteriormente em alopecia parcial, geralmente, na cabeça, orelha, pescoço e dorso, enquanto algumas áreas cobertas por pelos que não são pretos, podem ser normais. O diagnóstico é confirmado por características histopatológicas. Este artigo tem como objetivo relatar um caso de displasia folicular do pelo preto em um cão macho Fox Paulistinha de sete meses de idade mostrando alopecia restrita a áreas de pelos pretos, em que o diagnóstico foi confirmado por exames histopatológicos que mostraram displasia folicular associada ao acúmulo melânico no folículo piloso e no tecido dérmico profundo.

INTRODUCTION

Abnormalities in melanocytes have been described in the dog, occasionally associated with alopecia. Color-linked follicular dysplasias are linked to coat color. They include color dilution alopecia (CDA) and black hair

follicular dysplasia (BHFD), which some authors consider to be clinically identical (Carlotti, 1990).

Both CDA and BHFD (also known as 'dark hair follicular dysplasia') are primarily noninflammatory forms of truncal hair loss that occur in various breeds, mainly associated with certain coat colors (Muller & Kirk, 2013).

* Corresponding author: veronica.terra@ufms.br

BHFD in dogs was first described in 1972 as alopecia that is confined to black regions of the hair coat (Selmanowitz et al., 1972). It has been reported in a variety of breeds such as Bearded Collie, Saluki, Border collie, King Charles spaniel, Jack Russel terrier, and Gordon setter (Hargis et al., 1991; Bohnhorst et al., 2001). Analysis of the pedigree of a family of dogs with black hair follicular dysplasia has suggested an autosomal recessive mode of inheritance (Schmutz et al., 1998).

Clinical signs consist of alopecia or progressive hypotrichosis in a young animal of predisposed color and breed. Tan areas are spared in color dilution alopecia and only black areas are affected in black hair follicular dysplasia. Diagnosis of these two skin problems is based on a combination of clinical signs, hair microscopy, and skin histopathology (Selmanowitz et al., 1972; Muller & Kirk, 2013).

The most common histopathological findings are superficial and follicular orthokeratotic hyperkeratosis, variation of follicular activity with a high frequency of catagenic sequestration, melanin clusters within hair and hairy bulbs, hairy stems fractured with clusters of free melanin in the light of hair follicles and perifollicular melanophages. Moreover, there is dystrophy of hair follicles and shafts, numerous perifollicular, and mainly peribulbar, melanophages, and pigmentary incontinence (Carlotti, 1990; Guaguere, 1991; Hargis et al., 1991; Rothstein et al., 1998; Gross et al., 2005).

Irregularly distributed clumps of melanin are also found within the medulla and the cortex of hair shafts, and the inner root sheath. Those hair shafts frequently break within the hair canal resulting in a distorted follicular infundibulum which is filled with keratin squames, fragmented hairs, and large irregular clumps of melanin (Guaguere, 1991; Hargis et al., 1991).

Follicular dysplasia has no specific treatment, and secondary complications are piodermatitis and seborrhea. Synthetic retinoids, particularly the Etretinate, may be useful for the treatment in some cases (Muller & Kirk, 2013). This work aims to report a case of

black hair follicular dysplasia in a seven-month-old male dog Fox Paulistinha breed confirmed by histopathological examination.

CASE REPORT

A Fox Paulistinha male young dog was attended at the Veterinary Hospital of the Federal University of Mato Grosso do Sul (UFMS) showing hair loss. The animal had been found on the street three months before the consultation, showing at that time, generalized hair loss with few scabs on the head. At that moment he was taken to a pet shop where it was recommended Omega 3 and Sarolaner (Simparic®, sarolaner, Zoetis, Brasil).

After two monthly doses of Sarolaner there was regression of crusts and almost total repilation in white hair colored areas, but not in black zones. The animal was in good physical condition (Figure 1). Hematological examinations were performed and did not reveal any changes, as well as other exams, such as fungal culture and parasitological examination by skin scrapings, both with negative results, besides nonreagent serological tests for Leishmaniasis.

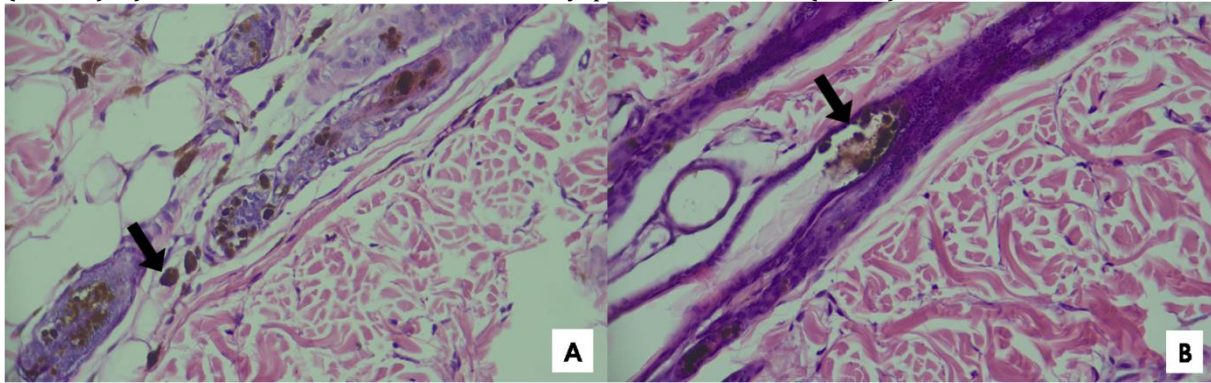
The skin biopsy was performed with the aid of an eight mm punch in two different skin areas, one from a black hair region and another one from an interface region between black and white areas of the hair coat. Histopathological findings showed moderate multifocal lamellar hyperkeratosis, epidermis with multifocal, discrete areas of spongiosis. In the basal region, there was severe, multifocal pigment incontinence, with melanin aggregation (Figure 2) and thick melanin eviction involving the interface.

The follicles exhibited moderate atrophic/dysplastic pattern with intense melanic accumulation between the lamellar keratin, associated with the deposition of melanin in the follicular contours. Sometimes, there was dense melanin eviction within the adipose tissue. These histopathological findings featuring follicular dysplasia associated with melanic accumulation in the hair shaft and in and deep dermal tissue led to the final diagnosis of black hair follicular dysplasia.

Figure 1. Bicolor (white and black), Fox Paulistinha, male, with approximately 7 months of age, presenting alopecia on the outside surface of the pinna and dorsal head region and other areas of black hair (arrows).

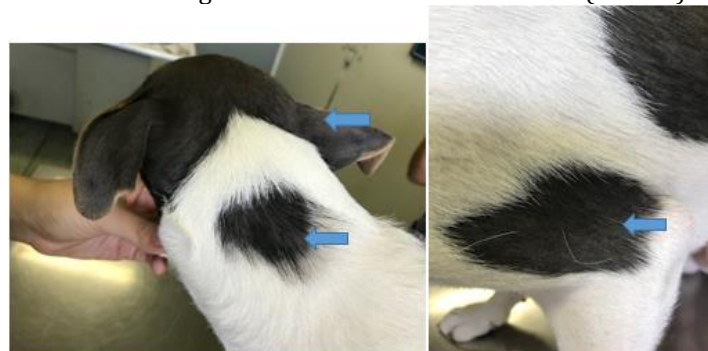

Figure 2. Dog, skin, black coat region. A) Atrophic follicles with irregular melanin deposits. Note the pigment outside the follicles (arrows). B) Presence of melanin clusters in the dysplastic hair follicle (arrow). HE, 100X.



DISCUSSION

Black Hair Follicular Dysplasia is an uncommon skin disease in dogs, and there are few reported cases published throughout the world. Despite BHFD has been reported in the early weeks of life of the animal (Selmanowitz et al., 1972; Dunn et al., 1995), it was not possible to determine the exact age signals appeared in this dog since it was rescued from the street showing the injuries.

Kim et al. (2005) reported progressive alopecia of black areas without itching, similar to this case. Various breeds may be affected as described in the literature, but the animal must be a bi or tricolor coat dog, as the animal of this report, which was bicolor (Dunn et al., 1995; Selmanowitz et al., 1972). Muller & Kirk (2013) say the altered areas are more obvious on the trunk, but there can also be involvement of the neck, and the distal ends of the members are always spared, corroborating the locations of lesions of the present report.

Trichography of the black hair reveals deformities in the hair shaft including unclear definition between the hair layers (medulla, cortex, and cuticle), an irregular outline of the hair shaft, and bulges of macromelanosomes, indicating excessive accumulation of melanin (Gross et al., 2005). Moreover, trichography findings also lead to the suspicion of BHFD in another report, further confirmed as BHFD by skin histopathological examination (Tatibana et al., 2012). Trichography was not performed in our study, once the definitive diagnosis should always be performed through histopathology.

The histopathological findings corroborated with those described by Rothstein et al. (1998) with the presence of clusters of melanin in dysplastic hair, which characterizes follicular dysplasia. Although Laffort-Dassot et al. (2002) say that histopathological findings are not specific enough to differentiate CDA from black hair follicular dysplasia, clinical data will support the final diagnosis of BHFD, since animal of this report was bicolor and the injuries were restricted to areas of the black coat. Besides, there were no areas of pigment diluted in the histopathological exam, which is a CDA feature (Kim et al., 2005).

No tests for endocrinopathies, such as hypothyroidism, have been requested, once the age of the animal was not compatible with this disease, and there were no signs of pyoderma or other systemic signs to suggest any endocrinopathy. Cruz et al. (2015) reported a dog with BHFD in which the diagnosis was established based on the results of the trichography and histopathologic examination, which, associated with the history and clinical signs, revealed clinical and micromorphological alterations compatible with BHFD, eliminating the need for hormonal dosage to rule out endocrine disorders that cause secondary follicular dysplasia, as in our case. Also, Kim & Park (2015) described a case of BHFD in a 7-year-old intact female black-spotted and white hair Shih-Tzu dog based on signalment and dermatologic examination.

In a retrospective study of skin biopsies from 72 dogs with follicular dysplasia and 102 dogs with endocrinopathy, Rothstein et al. (1998) noticed that the presence of abnormal melanin clumps in dysplastic hair shafts was characteristic of follicular dysplasia, which was compatible with our findings.

No specific therapeutic conduct was installed, in addition to baths with moisturizing shampoos, as Muller & Kirk (2013) point out that BHFD does not cause any systemic problems since it is a purely aesthetic problem. We also recommended to neuter the animal, since affected dogs should not be used for breeding due to the inherited nature of the disorder (Song et al., 2008).

CONCLUSIONS

BHFD is an unusual inherited skin disease, which does not lead to any systemic consequences, consisting only of an esthetic problem. The described case reinforces the need for diagnostic confirmation through a histopathological exam.

ACKNOWLEDGMENTS

We are grateful to VETPAT laboratory for having kindly ceded images of the histopathological exams.

REFERENCES

BOHNHORST, J.O.; HANSSEN, I.; MOEN, T. Antinuclear antibodies (ANA) in Gordon Setters with symmetrical lupoid onychodystrophy and black hair follicular dysplasia. *Acta Veterinaria Scandinavica*, n. 42, p. 323-329, 2001.

CARLOTTI, D.N. Canine hereditary black hair follicular dysplasia and colour mutant alopecia. Clinical and histopathological aspects. In: Von TSCHARNER, C., HALLIWELL, R.E.W., eds. *Advances in Veterinary Dermatology*, Vol. 1. Philadelphia: Baillière Tindall, p.43-6, 1990.

CRUZ, T.P.S.; NEVES, R.C.S.M.; CRUZ, F.A.C.S. et al. Displasia folicular do pelo preto em canino. *Acta Veterinaria Brasilica*, v.9, n.3, p.284-288, 2015.

DUNN, K.A.; RUSSELL, M.; BONESS, J.M. Black hair follicular dysplasia. *Veterinary Record*, n. 137, p. 412, 1995.

GROSS, T.L.; IHRKE, P.J.; WALDER, E.; AFFOLTER, V. K. Dysplastic diseases of the adnexa. In: GROSS, T.L.; IHRKE, P.J.; WALDER, E.; AFFOLTER, V. K., eds. *Skin diseases of the dog and the cat: clinical and histopathological diagnosis*. 2 ed. St Louis. Blackwell Science Ltd. p. 518-522, 2005.

GUAGUERE, E. Aspects histopathologiques et ultrastructuraux de l'alopecie des robes diluées: à propos d'un cas chez un Doberman Pinscher bleu. *Pratique Medicale et Chirurgicale de L'animal de Compagnie*, n. 26, p. 537-46, 1991.

HARGIS, A.M.; BRIGNAC, M.; AL BAGDADI, F. et al. Black hair follicular dysplasia in black and white Saluki dogs: differentiation from colour mutant alopecia in the Doberman Pinscher by microscopic examination of hairs. *Veterinary Dermatology*, n. 2, p.69-83, 1991.

KIM, J.H.; KANG, K.; SOHN, H.J.; WOO, G.H.; JEAN, Y.H.; HWANG, E.K. Color-dilution alopecia in dogs. *Journal Veterinary Science*, v. 6, n. 3, p. 259-261, 2005.

LAFFORT-DASSOT, C.; BECO, L.; CARLOTTI, D.N. Follicular dysplasia in five Weimaraners. *Veterinary Dermatology*, n. 13, p. 253-260, 2002.

MULLER, G.H.; KIRK, R.W. Congenital and Hereditary Defects. In: MILLER, W.H.; GRIFFIN, C.E. & CAMPBELL, K.L., eds. *Muller & Kirk's Small Animal Dermatology* 7th ed. St. Louis, Mo. Elsevier, Chap.12, p. 573-617, 2013.

ROTHSTEIN, E.; SCOTT, D.W.; MILLER, W.H. et al. A retrospective study of dysplastic hair follicles and abnormal melanization in dogs with follicular dysplasia or endocrine skin disease. *Veterinary Dermatology*, n. 9, p. 235-241, 1998.

SELMANOWITZ VJ, KRAMER KM, ORENTREICH N. Canine hereditary black hair follicular dysplasia. *Journal of Heredity*, n. 63, p. 43-44, 1972.

SCHMUTZ, S.M.; MOKER, J.S.; CLARK, E.G.; SHEWFELT, R. Black hair follicular dysplasia, an autosomal recessive condition in dogs. *Canadian Veterinary Journal* n. 39, p.644-646, 1998.

SONG, T.Y.; HUANG, H.P.; CHANG, P.H.; LIEN, Y.H. Canine Black Hair Follicular Dysplasia in a Chihuahua: a case report. *Journal of Veterinary Clinical Sciences*, v. 1, n.1, p. 21-23, 2008.

TATIBANA, L.S.; PAGLIONI, D. N.; VAL, A.P.C. Black hair follicular dysplasia in a Brazilian Terrier: a case report. *Revista Brasileira de Ciências Veterinárias*, v. 19, n. 1, p. 7-12, 2012.