








Original article

## Uterine adenomyosis in bitches and queens: occurrence and histopathological aspects

Adenomiose uterina em cadelas e gatas: ocorrência e aspectos histopatológicos

Lucien Roberta Valente Miranda de Aguirra<sup>1\*</sup> , Washington Luiz Assunção Pereira<sup>1</sup> , Marcella Katheryne Marques Bernal<sup>1</sup> , Sebastião Tavares Rolim Filho<sup>1</sup> , Paulo Henrique Leal Bertolo<sup>1</sup> , Eduardo Henrique Marsola<sup>1</sup>

<sup>1</sup> Universidade Federal Rural da Amazônia

### ARTICLE INFO

#### Article history

Received 02 May 2019

Accepted 11 July 2019

#### Keywords:

Reproductive system

Patholog

Domestic animals

### ABSTRACT

The goal of this study was to report the occurrence and histopathological aspects of uterine adenomyosis in bitches and queens. The sample consisted of 200 uteri from bitches (n = 100) and queens (n = 100) obtained from elective ovarian-salpingohysterectomies. The animals were classified according to age, having given birth, and contraceptive use. Samples of the uterine horns were collected following routine histological processing using slides stained with hematoxylin and eosin. The data obtained were analysed using the chi-square test, with 5% significance level. Uterine adenomyosis was confirmed in 12% of bitches and 3% of queens. Age had no influence on the occurrence of this disease; however, not having given birth and the use of contraceptives favoured its appearance in bitches. Microscopically, portions of endometrial glands and stroma were present in the circular and vascular myometrial strata, with normal and cystic characteristics and variations in the glandular epithelium. There was cystic-type luminal content, such as calcification, hyaline substance, polyps, and mucin. This study made it possible to conclude that uterine adenomyosis occurs more frequently in bitches than in queens, regardless of age groups. Nulliparous bitches using contraceptives were the most affected. This pathology showed variations with respect to location and histopathological aspects, with the cystic type exhibiting calcification, hyaline substance, polyps, and mucin inside the lumen. These findings are being reported for the first time in the veterinary literature.

### RESUMO

Objetivou-se com essa pesquisa relatar a ocorrência e os aspectos histopatológicos da adenomiose uterina em cadelas e gatas. Foram utilizados 200 úteros, de cadelas (n=100) e gatas (n=100), procedentes de ovariosalpingohisterectomias eletivas. Os animais foram classificados segundo a faixa etária, parição e uso de contraceptivos. Amostras dos cornos uterinos foram coletadas, seguindo-se ao processamento histológico de rotina, sendo as lâminas coradas pela hematoxilina e eosina. Os dados obtidos foram analisados pelo teste Qui-quadrado, com significância de 5%. A adenomiose uterina foi identificada em 12% das cadelas e 3% das gatas. Não houve influência na ocorrência dessa enfermidade quanto a faixa etária, porém a ausência de parição e o uso de contraceptivos favoreceram o aparecimento em cadelas. Microscopicamente, porções de glândulas e estroma endometrial estavam presentes no estrato miometrial circular e vascular, ocorrendo o tipo normal, cístico e variações no epitélio glandular. Houve presença de conteúdo luminal no tipo cístico, como calcificação, substância hialina, pólipos e mucina. Com esse estudo foi possível concluir que a adenomiose uterina ocorre com maior frequência em cadelas do que em gatas, independente da faixa etária. Cadelas nulíparas que utilizaram contraceptivos foram as mais afetadas. Essa patologia mostrou variações quanto a localização e aspecto histopatológico, exibindo no tipo cístico, calcificação, substância hialina, pólipos e mucina no interior do lúmen, sendo estes achados relatados pela primeira vez na literatura veterinária.

#### Palavras-chave:

Sistema reprodutor

Patologia

Animais domésticos

\* Corresponding author: [lucyaguirra@yahoo.com.br](mailto:lucyaguirra@yahoo.com.br)

## INTRODUCTION

Uterine adenomyosis is a benign non-neoplastic lesion resulting from the development of endometrial glands and stroma, preferably in the myometrium. Its occurrence is rare in domestic animals, being less common in queens than in bitches (KENNEDY et al., 1998; BULMAN-FLEMING, 2008).

The aetiology is still poorly known, and congenital malformations have been accepted by some authors (JUBB et al., 1993; SANTOS et al., 2008). However, other authors believe that hormonal disturbances and increased luminal pressure may be involved in the development of the disease (FERENCZY, 1998; BULMAN-FLEMING, 2008; PEREZ-MARIN et al., 2008).

Animals with uterine adenomyosis may or may not have clinical signs, which, when present, vary widely. This disease is usually an accidental finding associated with other ovarian or uterine disorders, such as cystic endometrial hyperplasia (SANTOS et al., 2008), pyometra, granulosa-cell tumour (ZANGHI et al., 2007), and ovarian cysts (PEREZ-MARIN et al., 2008). Vaginal discharge (SANTOS et al., 2008), emesis, inappetence, and abdominal pain (BULMAN-FLEMING, 2008) have been described in animals diagnosed with uterine adenomyosis only.

The definitive diagnosis is based on histopathological examination, as this uterine disease, when observed macroscopically, resembles uterine leiomyoma and adenoma (TAMADA et al., 2005; BULMAN-FLEMING, 2008).

This way, the goal of the present study was to report the occurrence and histopathological aspects of uterine adenomyosis in bitches and queens.

## MATERIALS AND METHODS

The present research was approved by the Ethics Committee on Animal Use (CEUA) of the Federal Rural University of Amazonia (UFRA), under Protocol No. 07/2012. We assessed 200 uteri, which were divided into bitches ( $n = 100$ ) and queens ( $n = 100$ ). They were randomly collected from elective ovarian-salpingohysterectomies (OSH) performed in healthy females, after clinical evaluation and preoperative blood count.

The animals were classified according to age groups ( $>6$  months to  $\leq 3$  years, and  $>3$  years to  $\leq 6$  years), having given birth (nulliparous/pluriparous), and contraceptive use (yes/no).

The uteri from OSH were obtained at the operating room and then cleaned under running water. The broad ligaments were removed in order to place the entire pieces in polyethylene containers with lids and 10% buffered formaldehyde solution for 48 hours.

For the histopathological analyses, we selected 3- to 5-mm thick longitudinal samples from the cranial, medial, and caudal regions of the uterine horns, processed according to the routine histological technique described by Tolosa et al. (2003), using slides stained with hematoxylin and eosin (HE) at the Animal Pathology Laboratory of UFRA. All slides were analysed by optical microscopy, and cases of uterine adenomyosis were classified according to the location and aspect of the endometrial glands.

The data obtained were statistically analysed using the chi-square test and the Statistical Analysis System (SAS, 1995), with 5% significance level.

## RESULTS

Of the total cases analysed, 12% (12/100) of the bitches and 3% (3/100) of the queens had uterine adenomyosis, with a statistically significant difference ( $p < 0.05$ ) between the species.

The age group did not represent a determining factor in the occurrence of this disease ( $p > 0.05$ ) in bitches or queens, given that the animals of both age groups were affected. Nulliparous bitches (91.67%) and pluriparous queens (66.67%) were the most affected by this disease, and this data was statistically significant for the canine species. Females of both species using contraceptives were more affected by uterine adenomyosis, with a statistically significant difference ( $p < 0.05$ ) for the canine species (Table 1).

It was not possible to observe cases of uterine adenomyosis macroscopically. However, this identification was possible during the histopathological exams. Microscopically, portions of endometrial glands and stroma were present in the circular myometrial stratum and, in one case, in the vascular stratum and the circular myometrial layer.

Due to the variety of ways in which this disease was observed, the processes were classified according to location (focal and diffuse) and aspect of endometrial glands (normal and cystic) in canine and feline species (Table 2).

Table 1 – Frequency of adenomyosis with respect to age, having given birth, and contraceptive use in canine and feline species.

Variables*	Species	
	Canine - N (%)	Feline - N (%)
<b>Age</b>		
>6 months to ≤3 years	7 (58.33) <sup>a</sup>	1 (33.33) <sup>a</sup>
>3 years to ≤6 years	5 (41.67) <sup>a</sup>	2 (66.67) <sup>a</sup>
Total	12 (100)	3 (100)
<b>Having given birth</b>		
Nulliparous	11 (91.67) <sup>a</sup>	1 (33.33) <sup>a</sup>
Pluriparous	1 (8.33) <sup>b</sup>	2 (66.67) <sup>a</sup>
Total	12 (100)	3 (100)
<b>Contraceptive use</b>		
No	3 (25) <sup>a</sup>	1 (33.33) <sup>a</sup>
Yes	9 (75) <sup>b</sup>	2 (66.67) <sup>a</sup>
Total	12 (100)	3 (100)

N = number of animals; % = percentage of animals.

\* Percentage of animals by species when related to age, having given birth, and contraceptive use. Those followed by different lowercase letters differed significantly according to the chi-square test ( $p < 0.05$ ).

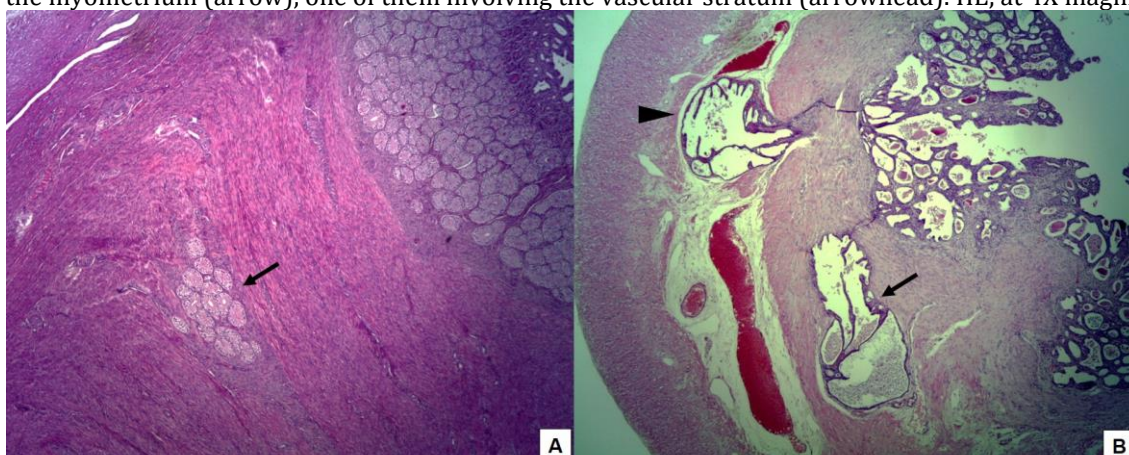
Table 2 – Frequency of adenomyosis with respect to location and aspect in canine and feline species.

Adenomyosis	Species	
	Canine	Feline
<b>Focal</b>		
Normal	5	2
Cystic	3	0
<b>Diffuse</b>		
Normal	0	1
Cystic	4	0
<b>Total</b>	<b>12</b>	<b>3</b>

Focal uterine adenomyosis referred to alteration of a single portion of the myometrium, where endometrial glands and stroma were present (Figure 1A). In diffuse uterine adenomyosis, several portions of the

myometrium were affected at the same time, and, in one case, it also occurred in the vascular stratum (Figure 1B). In all cases, the segment of the myometrial layer that exhibited this disease was thicker and more irregular.

Figure 1 – A. Focal adenomyosis in queens' uteri. Endometrial glands and stroma in a single portion of the myometrium (arrow). HE, at 10X magnification; and B. Diffuse adenomyosis in bitches' uteri. Endometrial glands and stroma in two portions of the myometrium (arrow), one of them involving the vascular stratum (arrowhead). HE, at 4X magnification.



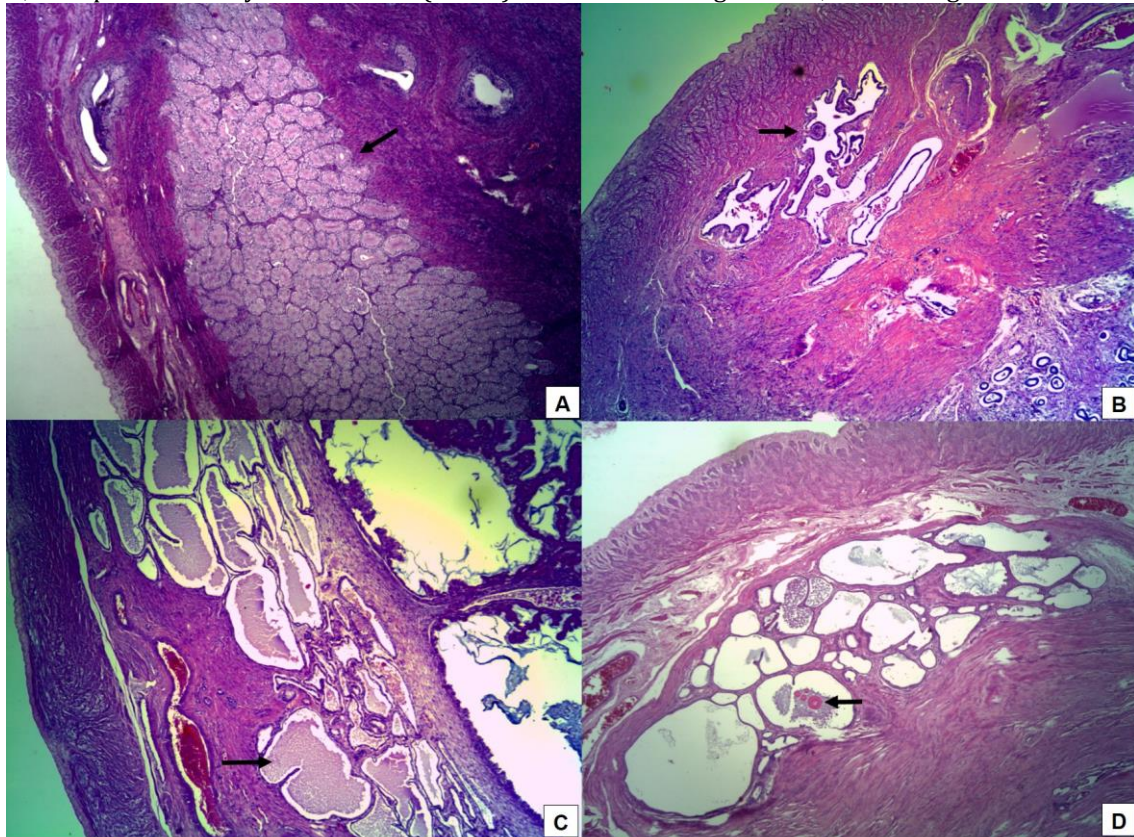
The aspect was considered normal when the endometrial glands exhibited usual sizes and shapes (Figure 2A), being composed of simple cubic epithelium. In the cystic aspect, changes in the size and shape of the endometrial glands were observed, showing cystic formations with epithelium ranging from cubic,

prismatic, stratified, and mucous with raised edge and polyploid formations projecting into the glandular lumen (Figure 2B). In one case, we observed calcification of several glands. In two cases, the glandular lumen contained granular, basophilic, and amorphous material (mucin) (Figure 2C), and another case exhibited



homogeneous acidophilic material with hyaline property (Figure 2D).

Figure 2 – Adenomyosis in bitches' uteri: A. Endometrial glands and stroma with normal aspect in a circular myometrial region (arrow); HE, at 20X magnificence; B. Cystic endometrial gland in the circular myometrium with polypoid projection to the glandular lumen (arrow); HE, at 20X magnificence; C. Large amount of cystic endometrial glands in the circular myometrium containing mucin (arrow); HE, at 20X magnificence; and D. Cystic endometrial glands in the circular myometrium, with presence of hyaline material (arrow) in the lumen of a gland. HE, at 20X magnificence.



## DISCUSSION

Uterine adenomyosis is occasionally cited in the veterinary literature. There are no studies determining the rate of occurrence in feline species, even though Kennedy et al. (1998) and Bulman-Fleming (2008) had mentioned that this disease was less common in queens than in bitches. In this sense, the present study reinforces this idea by having observed a lower occurrence rate of this pathology in queens in comparison to bitches.

In the canine species, Malm (1991) recorded a higher percentage than that obtained in the present study, with 34.29% (24/70) of the disease. However, in that study, the uteri assessed came from therapeutic OSH, unlike in the present study, given that the material that we analysed belonged to elective OSH.

Regarding the age groups, there are no previous studies addressing predisposition according to age with respect to the development of uterine adenomyosis in bitches and queens. In the present study, this variant was not significant for adenomyosis involvement in the species assessed. Nevertheless, this condition is commonly identified in senile females, as reported by Perez-Marin et al. (2008) in an eight-year-old bitch, Karagiannis et al.

(2011) in an 11-year-old bitch, and Tamada et al. (2005) in a 13-year-old bitch. Regarding queens, Bulman-Fleming (2008) recorded this pathology in a 12-year-old queen.

Nulliparous bitches that used contraceptives exhibited a higher occurrence of uterine adenomyosis, whereas queens did not exhibit predisposition caused by having given birth or contraceptive use. In this respect, the veterinary literature does not have studies correlating having given birth with the incidence of this uterine alteration, which has already been reported by Karagiannis et al. (2011) in a nulliparous bitch.

The use of progestogens has already been mentioned by Bulman-Fleming (2008) as a contributing factor in the development of uterine adenomyosis in queens. Hart (1990) stated that chronic estrogen stimulation induced this disease in domestic and laboratory animals. Those studies suggest that contraceptive use may play an important role in the development of uterine adenomyosis. In addition, other authors have reported that the incidence of this condition may be markedly increased in animals with systemic exposure to various hormonal agents, including prolactin (OSTRANDER et al., 1985; NAGASAWA et al., 1987; GREAVES; WHITE, 2006).

Macroscopically, it was not possible to observe the presence of adenomyosis in the analysed uteri, which corroborates the reports of Dow (1962) and Jubb et al. (1993), who referred this pathology to incidental findings. It is worth mentioning that uterine adenomyosis can be macroscopically confused with uterine neoplasms, such as leiomyoma and adenoma in early stages (MOULTON, 1990).

The microscopic findings of the present study are similar to those observed by Santos et al. (2008), who reported uterine adenomyosis found in focal and diffuse forms, isolated or grouped, invading the myometrium, as well as great variation in the epithelial coating.

In addition, Kim et al. (2010) observed that proliferation of endometrial glands and stroma in the myometrium did not promote compression of adjacent muscle fibres, which is in line with the findings of the present study.

In the cystic uterine adenomyosis observed in the present study, the presence of calcification, hyaline substance, polyps, and mucin inside the lumen are changes not yet recorded in the veterinary literature. This way, our data bring new information and questions about this disease.

## CONCLUSION

Uterine adenomyosis affected more bitches than queens, with low rates of occurrence in both species regardless of age. Nulliparous bitches that used contraceptives were most affected. Such pathology showed variations regarding location and histopathological aspects. The cystic type exhibited calcification, hyaline substance, polyps, and mucin inside the uterine lumen, and these findings are being reported for the first time in the veterinary literature.

## REFERENCES

BULMAN-FLEMING, J. A rare case of uterine adenomyosis in a Siamese cat. *Canadian Veterinary Journal*, v. 49, p. 709-712, 2008.

DOW, C. The cystic hyperplasia-pyometra complex in the cat. *Veterinary Record*, v. 74, p. 141-147, 1962.

FERENCZY, A. Pathophysiology of adenomyosis. *Human Reproduction Update*, v. 4, p. 312-322, 1998.

GREAVES, P.; WHITE, I.N.H. Experimental adenomyosis. *Best Practice & Research Clinical Obstetrics & Gynaecology*, v. 20, n. 4, p.1-8, 2006.

HART, J.E. Endocrine pathology of estrogens species differences. *Pharmacology & Therapeutics*, v. 47, p. 203-218, 1990.

JUBB, K.V.F.; KENNEDY, P.C.; PALMER, N. *Pathology of Domestic Animals*. 4.ed. San Diego: Academic Press, 1993. 2180p.

KARAGIANNIS, G.S.; PELEKANIS, M.; LOUKOPOULOS, P. et al. Canine Uterine Leiomyoma with Epithelial Tissue Foci, Adenomyosis and Cystic Endometrial Hyperplasia. *Case Reports in Veterinary Medicine*, v. 11, p. 1-4, 2011.

KENNEDY, P.C.; CULLEN, J.M.; EDWARDS, J.F. et al. *World health organization histological classification of tumors of the genital*

*system of domestic animals*. Washington DC: Armed Forces Institute of Pathology, p.24-31, 1998.

KIM, H.S.; KANG, S.; ZHANG, H. et al. Uterine Adenomyosis in Beagle Dogs. *Laboratory Animal Research*, v. 26, n. 2, p. 211-213, 2010.

MALM, C. *Aspectos clínicos e alterações morfológicas uterinas e ovarianas em cadelas submetidas a ovariosterectomia por indicação terapêutica*. 1991. 120f. Dissertation (Master's degree in Veterinary Medicine) – Faculty of Veterinary, Federal University of Minas Gerais, Belo Horizonte, Brazil.

MOULTON, J.E. *Tumours in Domestic animals*. London: University of California Press, 1990. 665 p.

NAGASAWA, H.; ISHIDA, M.; MORI, T. Effects of treatment with prolactin or progesterone on the coincidence of mammary tumors and uterine adenomyosis in young SHN mice. *Laboratory Animal Science*, v. 37, p. 200-202, 1987.

OSTRANDER, P.L.; MILLS, K.T.; BERN, H.A. Long-term responses of the mouse uterus to neonatal diethylstilbestrol treatment and to later sex hormone exposure. *Journal of the National Cancer Institute*, v. 74, p. 121-135, 1985.

PEREZ-MARIN, C.C.; MOLINA, L.; DOMINGUEZ, J.M. et al. Incidental finding of uterine adenomyosis in a bitch with reproductive disorders: a case report. *Veterinarni Medicina*, v. 53, n. 11, p. 636-640, 2008.

SANTOS, I.B.; MIRANDA, L.H.M.; PIZZOLATO, F. et al. Adenomiose focal e difusa em cadelas. *Revista de Ciências da Vida*, v. 28, n. 1, p. 79-83, 2008.

STATISTICAL ANALYSIS SYSTEM. *SAS user's guide: statistics*. Versão 5. Cary: SAS, 1995. 943p.

TAMADA, H.; KAWATE, N.; INABA, T. et al. Adenomyosis with severe inflammation in the uterine cervix in a dog. *Canadian Veterinary Journal*, v. 46, p. 333-334, 2005.

TOLOSA, E.M.C.; BEHMER, O.A.; FREITAS-NETO, A.G. *Manual de técnicas para histologia normal e patológica*. São Paulo: Manole, 2003. 331 p.

ZANGHI, A.; CATONE, G.; MARINO, G. et al. Endometrial polypoid adenomyomatosis in a bitch with ovarian granulosa cell tumour and pyometra. *Journal of Comparative Pathology*, v. 136, p. 83-86, 2007.