



Original Article

Comparative anatomical description of brain hemisphere surfaces in toninha dolphin and humans

Karina Martinez Gagliardo¹, Cristiane Ruiz², Naianne Kelly Clebis³, Carolina Bertozzi⁴

¹ PhD Morphological Sciences, Faculty of Veterinary Medicine, Monte Serrat University Center (UNIMONTE), Santos, São Paulo, Brazil.

² PhD Morphological Sciences, Department of Human Anatomy, São Camilo University Center, São Paulo, São Paulo, Brazil.

³ PhD Morphological Sciences, Department of Morphology, Federal University of Rio Grande do Norte - UFRN, Natal, Rio Grande do Norte, Brazil.

⁴ PhD Morphological Sciences, Department of Marine Biology, São Paulo State University – UNESP, São Vicente, São Paulo, Brazil.

ARTICLE INFO

Article history

Received 29 September 2016

Received in revised form 03 March 2017

Accepted 03 March 2017

Keywords:

Comparative anatomy

Brain

Pontoporia blainvillei

ABSTRACT

Pontoporia blainvillei (cetacean order and odontoceti suborder), popularly known in Brazil as Toninha, is a small dolphin with a long, thin beak found on the southern shore waters of the western Atlantic. The brain development of dolphins (expressed by the encephalization coefficient) in relation to body size is quite high, and is second only to humans. This high correlation in brain development between dolphins and humans was targeted in this research to describe and compare the morphology of cerebral hemisphere surfaces of these two species. Five brains of *Pontoporia blainvillei* donated by the BioPesca Project (a non-governmental organization) were analyzed. The brains were fixed in 20% formaldehyde solution for further description and comparison to human brains described in books of neuroanatomy. The telencephalon of *Pontoporia blainvillei* is rostrally tapered and expanded at the caudal end and it has a greater number of folds/gyrus when compared to human species. Some encephalic grooves/sulcus are similar to grooves found in the human species, such as the cruciate sulcus (central sulcus), lateral fissure (Sylvian cleft), cingulate sulcus and calcarine sulcus. The same encephalic lobes are seen in both species; however the parietal and temporal lobes are highly developed in the *Pontoporia blainvillei*. These differences are associated with specific function of the species, as the presence of the an efficient auditive system in dolphins.

INTRODUCTION

Dolphins are mammals (Order Cetacea) perfectly adapted to the aquatic environment (FOWLER; CUBAS, 2001; HETZEL; LODI, 1993; JEFFERSON et al., 1993). They are subdivided into three sub-orders: Archeoceti (extinct), Mysticeti and Odontoceti. The Odontoceti suborder is represented by toothed cetaceans, with the presence of only a single breathing hole and asymmetrical skull (BERTA et al., 2006). They have high cognitive activity, demonstrating convergent behavioral skills among the most developed primates (the human species) (MARINO et al., 2007).

Pontoporia blainvillei (*P. blainvillei*) (Suborder Odontoceti) is a dolphin popularly known as Fransiscana, or in Brazil as *Toninha*, *Boto-garrafa* or *Boto-cachimbo* (CRESPO et al., 1998; MOREIRA; SICILIANO, 1991), it is a small dolphin, grayish in color with a pointed and long beak (CRESPO et al., 1998; MOREIRA; SICILIANO, 1991) that can be found on the south coast of the western Atlantic, preferably in shallow waters and in estuary regions. It is currently on the Official List of Brazilian Fauna and Flora Species Threatened by Extinction (ICMBio, 2014) due to pollution of its ecosystem and local fishing activities (BERTOZZI, 2009; BERTOZZI; ZERBINI, 2002; COSTA et

* Corresponding author: karinamg79@uol.com.br

al., 2012; NETTO; DI BENEDITTO, 2008; OTT et al., 2002; SICILIANO, 2002).

Among the changes that have occurred in the evolution of the cetacean order with respect to shape and body physiology, the less obvious but most significant occurred in relation to brain size and morphology (MARINO, 2004). One of the most fascinating features of odontoceti is their exceptional telencephalon size and dense neocortex (MARINO, 2002; OELSCHLÄGER; OELSCHLÄGER, 2002; OELSCHLÄGER, 2008). The brain size in this suborder expressed by encephalization quotient (EQ = brain to body mass ratio) is superior to modern non-human anthropoid primates, second only to the human species (MARINO, 1998; MARINO; MCSHEA; UHEN, 2004a).

It is known that during central nervous system phylogenetic evolution, brain structures related to behavior and cognitive and emotional functions evolved in complex ways. It is likely that adaptive needs have generated brain expansion, consequently resulting in greater imbrication of brain folds (SCHMIDEK; CANTOS, 2008). Large brain development areas in odontoceti are closely related to the auditory system, given the need for an efficient echolocation mechanism that allows dolphins to get information about other animals and the environment, allowing for navigation and communication (MARINO et al., 2003b; MARINO; MCSHEA; UHEN, 2004a; MARINO et al., 2007; OELSCHLAGER; OELSCHLAGER, 2002; OELSCHLÄGER, 2008).

A morphological correspondence between size and degree of encephalic gyrus is observed between *P. blainvillei* and primates (SCHWERDTFEGER; OELSCHLÄGER; STEPHAN, 1984). The high degree of cortical gyrification in the telencephalon of many cetaceans are not encountered in any mammal, including humans (MARINO, 2007). However, the cerebral hemispheres of dolphins are smaller when compared to humans, not completely overlaying the cerebellum and the relatively thin cortex (MARINO, 2004; RIDGWAY; BROWNSON, 1984).

Given the high correlation between the brains of cetaceans and the most intelligent species inhabiting the earth, the human species, this study aims to describe the morphology of brain hemisphere surfaces in *P. blainvillei*, comparing lobes, gyri, and sulci of this species with the human species. The results obtained from this comparative study are important for developing the biological sciences, especially neuroscience.

MATERIALS AND METHODS

Five brains of male *P. blainvillei* obtained from animals accidentally caught in fishing nets in the southern coast of São Paulo - Brazil were used. The brains examined

were donated by the BioPesca Project, a non-governmental organization that researches fishing activities and their relationship with dolphins and sea turtles in the municipalities of Ubatuba, Guarujá, Santos, Praia Grande, Mongaguá and Itanhaem, São Paulo, Brazil. This study was approved by the ethics committee for the use of animals at the São Camilo University Center, CEUA (05/14).

Biometric data such as weight (kg) and total length (cm) of *P. blainvillei* were collected and age was estimated by the total length of the animal (BERTOZZI et al., 2010).

After verification of biometric parameters, the brain was removed from the skulls. The brain was carefully removed by performing a bone window in the occipital bone and immediately placed in a 20% formaldehyde-fixing solution. After a minimum period of 48 hours, morphological description was performed (lobes, gyri, and sulci) of the dorsolateral, medial and ventral surfaces of the cerebral hemispheres. The morphological description of the brain had a comparative approach to the morphological description of human brains found in neuroanatomy books and atlases/manuals.

RESULTS

Biometric data (body weight and total length) and age estimated by total animal length (BERTOZZI et al., 2010) of *P. blainvillei* used in this study are shown in Table 1.

Table 1 – Biometric data (body weight in kilograms - Kg and length in centimeters - cm) and estimated age of *Pontoporias blainvillei*.

ANIMAL	Body weight (Kg)	Length (cm)	Estimated age*
1	8.5	90	sub-adult
2	13.5	111	adult
3	11.5	105	sub-adult
4	10	94	sub-adult
5	9.8	89.5	juvenile

*juvenile males - total length < 90 cm; sub-adult males - total length >90cm and <107 cm; adult males - total length > 107 cm (BERTOZZI et al., 2010).

General aspects of *Pontoporia blainvillei* and human telencephalon

In absolute terms, the telencephalon of *P. blainvillei* is smaller when compared to the telencephalon of human species, it is rostrally tapered (corresponding to the term anterior in human anatomical nomenclature) and expanded at the caudal end (corresponding to the term posterior in human anatomical nomenclature). It displays a dorsoventral flattening and a greater number of gyrus.

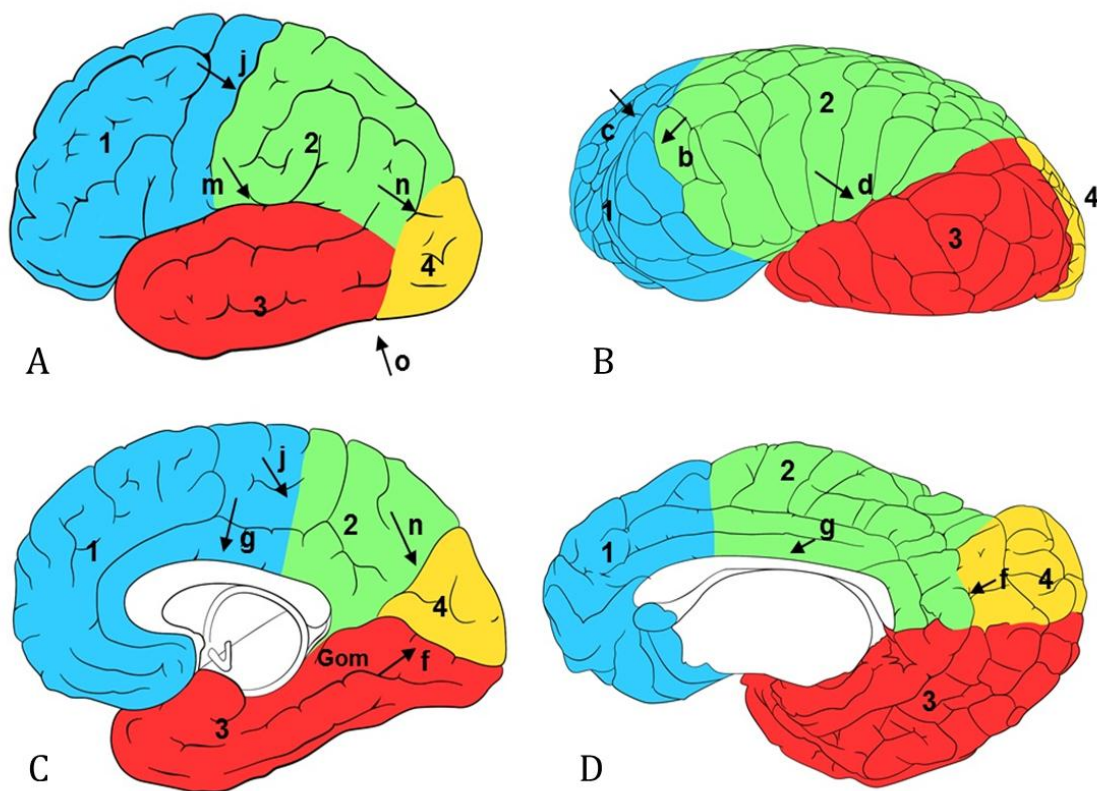
The telencephalon in *P. blainvillei* as well as in the human species is composed of two cerebral hemispheres

(left and right) partially separated by the longitudinal fissure, with the bottom formed by the corpus callosum, and is the main connection between the hemispheres. In humans, each hemisphere has three poles: an anterior known as the frontal pole, a posterior known as occipital pole, a medium pole known as temporal pole, and three surfaces: superolateral surface, which is round; medial surface, which is flat; and inferior surface, which is irregular. In *P. blainvillei*, the frontal pole is also named the rostral pole according to the terms of veterinary anatomical direction, and known as the orbital pole. The other poles and faces/surfaces coexist, and can be equivalent; however, the veterinary anatomical

nomenclature refers to the posterior pole as the caudal pole, to the superolateral surface as the dorsolateral surface, and to the inferior surface as the ventral surface.

Divisions in brain lobes are related to skull bones, except for the insula lobe, which is surrounded by adjacent lobes. Thus, the telencephalon in *P. blainvillei* and in humans is divided into a frontal lobe, parietal lobe, temporal lobe and occipital lobe (Figure 1A-D). Despite both species presenting the insula lobe, this will not be described since it is not visible on the surface of the encephalon.

Figure 1 – (A) Human telencephalon lobes seen laterally. (B) *Pontoporia blainvillei* telencephalon lobes seen laterally. (C) Human telencephalon lobes seen medially. (D) *Pontoporia blainvillei* telencephalon lobes seen medially.



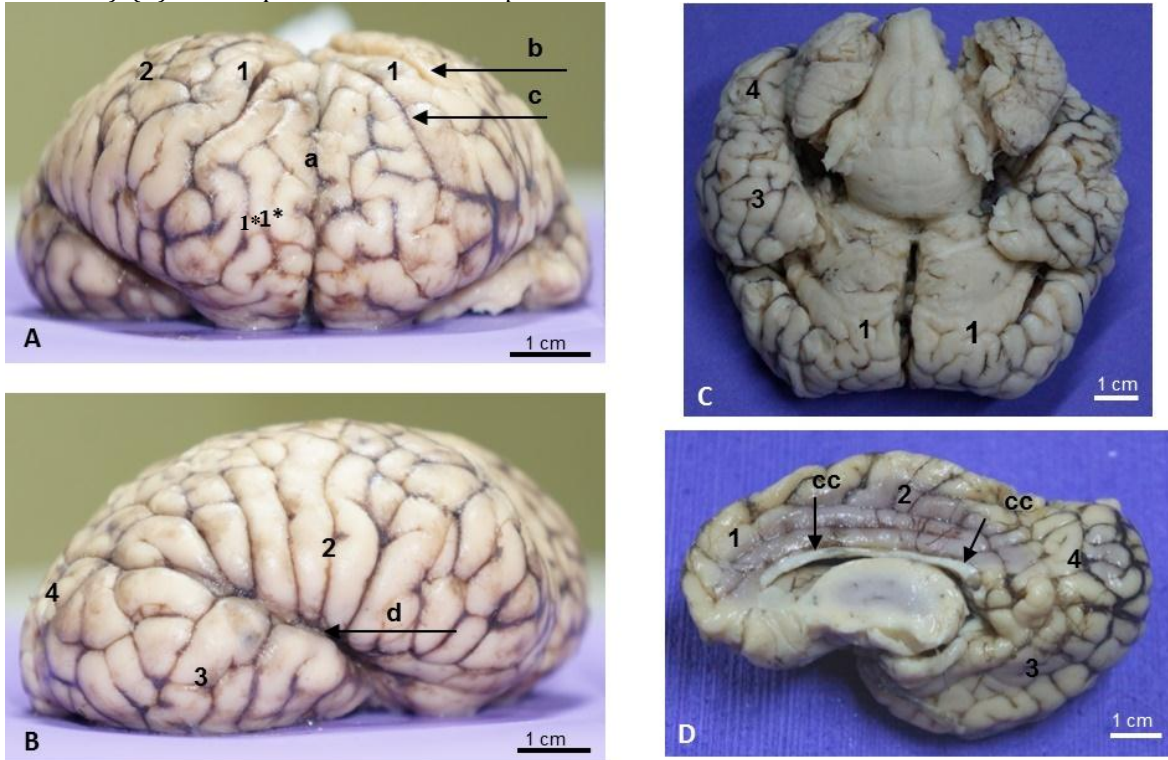
1- frontal lobe, 2 - parietal lobe, 3 - temporal lobe, 4 - occipital lobe, b - entolateral sulcus or paralimbic cleft, c - cruciate sulcus, d - lateral fissure or Sylvius cleft, f - calcarine sulcus, g - callosal sulcus, j - central sulcus, m - lateral sulcus or Sylvius fissure, n - parieto-occipital sulcus, o - occipital incisure, Gom- medial occipitotemporal gyrus. Source: The author, 2017.

In *P. blainvillei*, the frontal lobe region extends to the rostral region of the brain until the entolateral sulcus (paralimbic cleft) (Figure 1B; Fig 2A). In humans, the frontal lobe extends to the anterior region of the brain until the central sulcus (Figure 1A and 1C). The frontal lobe in *P. blainvillei*, which corresponds to the frontal lobe in humans, is called the orbital lobule, which is bordered by the cruciate sulcus (corresponding to the central sulcus in humans).

The parietal lobe in *P. blainvillei* (Figure 2A, 2B and 2D) lies between the frontal lobe and occipital lobe. It has the entolateral sulcus (or paralimbic cleft) as its rostral limit

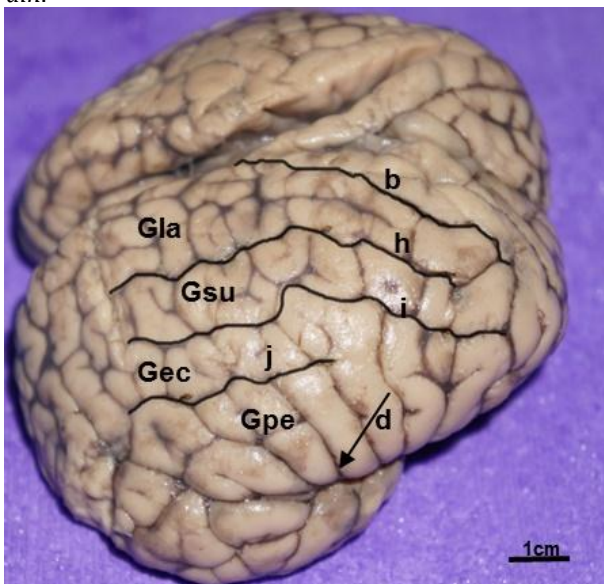
(Figure 1B; Figure 2A; Figure 3), and the extremities of the superior lateral sulcus (ectolateral sulcus), the intermediate lateral sulcus (suprasylvian sulcus) and the inferior lateral sulcus (ectosylvian sulcus) as its caudal limit (Figure 3). It involves the telencephalon from the limbic lobule (on the medial side of the brain) until the lateral fissure (Sylvian cleft) (on the lateral side of the brain) (Figure 4). The parietal lobe in humans extends from the central sulcus (anterior limit) to the parieto-occipital sulcus (posterior limit), extending between these limits from the medial surface up to the lateral sulcus (Sylvian fissure) in the lateral surface (Fig 1A and 1C).

Figure 2 - (A) Telencephalon lobes in *Pontoporia blainvillei* rostral surface (anterior view in humans). (B) Telencephalon lobes in *Pontoporia blainvillei* lateral surface. (C) Telencephalon lobes in *Pontoporia blainvillei* ventral surface (inferior surface in humans). (D) Telencephalon lobes in *Pontoporia blainvillei* medial surface.



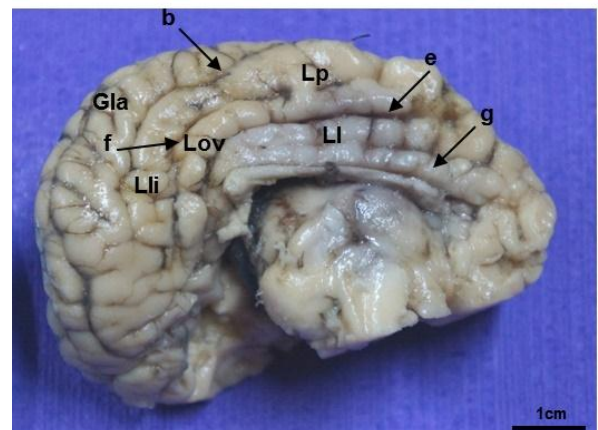
a - longitudinal fissure, b - entolateral sulcus or paralimbic cleft, c - cruciate sulcus, d - lateral fissure or Sylvius cleft, cc - corpus callosum, 1- frontal lobe, 1* orbital lobule, 2 - parietal lobe, 3 - temporal lobe, 4 - occipital lobe. Source: The author, 2017.

Figure 3 - Dorsolateral surface of *Pontoporia blainvillei* brain.



b- entolateral sulcus or paralimbic cleft, d- lateral fissure or Sylvian cleft, h - superior lateral sulcus or ectolateral sulcus, i- intermediate lateral sulcus or suprasylvian sulcus, j- inferior lateral sulcus or ectosylvian sulcus, Gla- lateral gyrus, Gsu- suprasylvian gyrus, Gec- ectosylvian gyrus, Gpe - perisylvian gyrus. Source: The author, 2017.

Figure 4 - Telencephalon lobes in *Pontoporia blainvillei* medial surface.

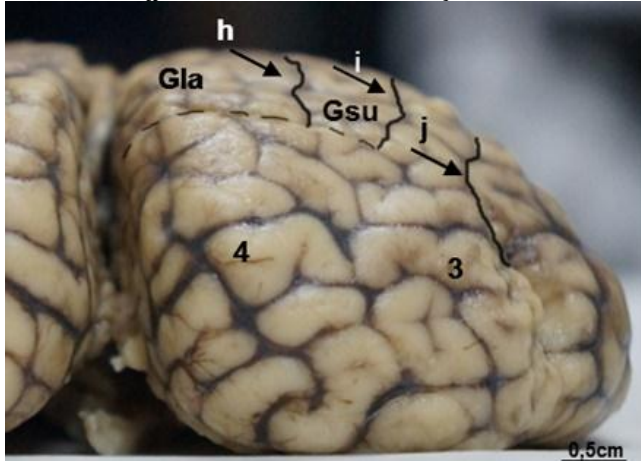


b - entolateral sulcus or paralimbic cleft, e - limbic sulcus, f - calcarine sulcus, g - callosal sulcus, Li - limbic lobule, Lp - paralimbic lobule, Gla - lateral gyrus, Lli - lingual lobule, Lov - oval lobule. Source: The author, 2017.

The temporal lobe in *P. blainvillei* extends from the lateral fissure (Sylvian cleft) up to the medial-ventral region (Figure 1B and 1D; Figure 2B-D). The caudal limit of the temporal lobe is very difficult to describe, since no characteristic sulcus divides the temporal and occipital areas from one another. In this study, the division of the regions was established through a vertical line from the

end of the intermediate lateral groove (or suprasylvian groove) to the most ventral region of the caudal face (Figure 5). In humans, the temporal lobe extends from the lateral sulcus (Sylvian fissure) up to the medial occipitotemporal gyrus. It has the parieto-occipital sulcus and pre-occipital incisor on the lateral surface as posterior limits (Figure 1A and 1C).

Figure 5 – Caudal pole of *Pontoporia blainvillei* brain – caudal view (posterior view in humans).



h- superior lateral sulcus or ectolateral sulcus, i- intermediate lateral sulcus ou suprasylvian sulcus, j- inferior lateral sulcus or ectosylvian sulcus, Gla- lateral gyrus, Gsu- suprasylvian gyrus, 3- temporal lobe, 4- occipital lobe. Source: The author, 2017.

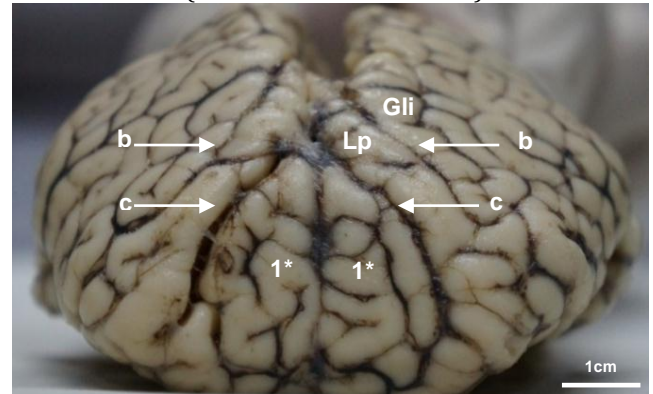
The occipital lobe in *P. blainvillei* is caudally located to the parietal lobe and caudal-laterally to the temporal lobe (Figure 1B and 1D; Figure 2B-D). It comprises the lingual lobule and the caudal region of the lateral gyrus on the medial side of the brain (Figure 4). It has its dorsal-lateral limit at the ends of the superior lateral sulcus (or ectolateral sulcus) and intermediate lateral sulcus (suprasylvian sulcus). The occipital lobe in humans is bordered by the parieto-occipital sulcus and the pre-occipital incisure on the lateral surface. The medial limit of this lobe is determined by the parietal-occipital sulcus to the medial occipitotemporal gyrus, which is below the calcarine sulcus (Figure 1A and 1C).

Configuration of telencephalon surfaces in *P. blainvillei*

• Rostral pole (orbital pole)

The rostral pole of the cerebral hemispheres in *P. blainvillei*, also known as the orbital pole, is mainly composed of the orbital lobule, defined by the cruciate sulcus (corresponding to the central sulcus in humans). Caudal to this sulcus is the paralimbic lobule, followed by the entolateral sulcus (paralimbic cleft). The paralimbic lobule and the lateral gyrus can also be observed in the rostral pole (Figure 6).

Figure 6 – Rostral pole of *Pontoporia blainvillei* brain – rostral surface (anterior view in humans).



b- entolateral sulcus or paralimbic cleft, c- cruciate sulcus, Lp - paralimbic lobule, Gli - limbic gyrus, 1* - orbital lobule. Source: The author, 2017.

• Dorsolateral Surface

The dorsolateral surface of the brain hemispheres in *P. blainvillei* is organized in a series of grooves and gyrus around the lateral fissure (Sylvian cleft). Three large grooves can be seen around the lateral fissure (Sylvian cleft): the inferior lateral sulcus (ectosylvian sulcus), intermediate lateral sulcus (suprasylvian sulcus) and superior lateral sulcus (ectolateral sulcus) (Figure 3).

The grooves defining/outline the gyrus: perisylvian (around the lateral fissure), ectosylvian (dorsal to the inferior lateral sulcus), suprasylvian (dorsal to the intermediate lateral sulcus) and lateral (dorsal to the superior lateral sulcus) (Figure 3)

• Caudal pole

The caudal pole of the cerebral hemispheres in *P. blainvillei*, also known as occipital pole, is mainly characterized by the occipital lobe and the caudal end of the temporal lobe (Figure 5).

• Medial Surface

The medial surface of the cerebral hemispheres of *P. blainvillei* is basically divided at the limbic lobule (which corresponds to the cingulate gyrus in humans), paralimbic lobule, lingual lobule, oval lobule, lateral gyrus and gyrus of the temporal lobe. The limbic lobule is located above the corpus callosum, and the paralimbic lobule is between the limbic lobule and the lateral gyrus. The latter is referred to as the most dorsal gyrus. The lingual lobule is located between the lateral gyrus and the oval lobule (Figure 4).

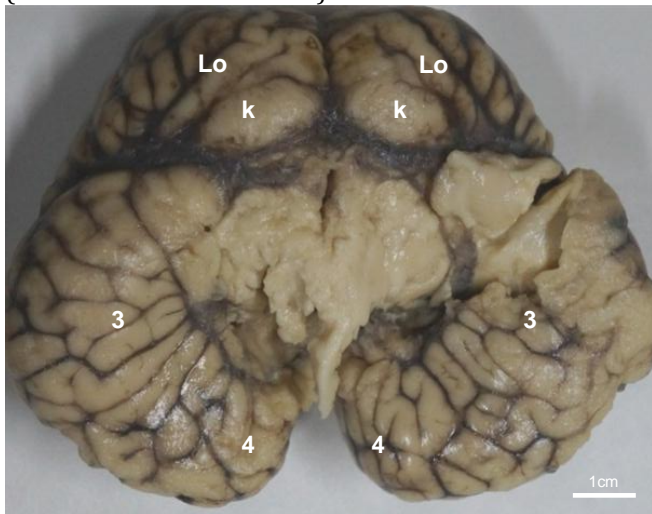
The limbic lobule is separated from the corpus callosum by the corpus callosum sulcus (or callosal sulcus) and from the paralimbic lobe by the limbic sulcus (which corresponds to the cingulate sulcus or supraesplenial groove in humans). The paralimbic lobule is separated

from the lateral gyrus by the entolateral sulcus (paralimbic cleft). The paralimbic lobule is divided into two lobules at its caudal region, the lingual lobe and the oval lobe. The groove separating the two lobes is the calcarine sulcus. The lingual lobule is dorsal to the calcarine sulcus, and the oval lobule is ventral to it (Figure 3).

• Ventral Surface

The orbital lobe and the olfactory tubercles can be observed on the ventral surface of the cerebral hemispheres in *P. blainvillei*; The occipital lobe and temporal lobe can also be observed (Figure 7).

Figure 7 – Ventral surface of *Pontoporia blainvillei* brain (inferior surface in humans).



Lo- orbital lobule, k-olfactory tubercle, 3- temporal lobe, 4- occipital lobe. Source: The author, 2017.

DISCUSSION

Although odontoceti have a high encephalization index (EQ = brain to body mass ratio), this data refers almost exclusively to the Delphinidae family (MARINO et al., 2004b). *P. blainvillei* (Pontoporiidae family) has one of the lowest encephalization indexes among Odontoceti (MARINO, 2004), despite the amount of gyri in the telencephalon of this species surpassing even the species with the highest encephalization index, the human species. Literature reports that high rates of encephalization correlate to high cognitive activity (MARINO et al., 2003b; MARINO et al., 2004b; MARINO et al., 2007) and that adaptive needs culminate in brain growth and therefore in a greater number of gyrification (SCHMIDEK; CANTOS, 2008). This, however, does not relate to *P. blainvillei*, since this species has one of the lowest encephalization indexes (MARINO et al., 2003b; MARINO et al., 2004a) and a large amount of gyri.

The large amount of gyri can be explained by a possible increase in glial cells (MANGER, 2006) and not from an increase in the number of neurons that results in greater

cognitive activity in this species. A high convolutions index (or gyrification) is also observed in other species of cetaceans such as in the common dolphin (*Delphinus delphis*) (MARINO, 2007; OELSCHLAGER et al., 2010), in the *Orcinus orca* (orca) (MARINO et al., 2004b), in the *Kogia simus* (dwarf sperm whale) (MARINO et al., 2003a) and in *Tursiops truncatus* (bottlenose dolphin) (MARINO et al., 2001).

The high level of convolutions in odontocetes follows a positive slope of the brain's rostral region (anterior in human) to the caudal region (posterior in human). This characteristic relates to the increased development of the parietal and temporal regions in the orbital region (frontal in humans). This arrangement is different from other mammals, including humans, but common among cetaceans (MARINO et al., 2001).

Differences in the encephalon shape in *P. blainvillei* when compared to other species of terrestrial mammals, particularly humans, is closely linked to rostrocaudal shortening of the cranial cavity, due to the migration of the nasal openings to the top of the skull (MARINO, 2001). Thus, the encephalon of *P. blainvillei* is proportionally taller and wider than the brains of terrestrial mammals, reflecting the changes in the skull of cetaceans (OELSCHLAGER; OELSCHLAGER, 2002).

The lobes found in *P. blainvillei* resemble the lobes in humans, although the demarcations between them do not follow the same sulcus pattern. Nevertheless, the cruciate sulcus (or central sulcus in humans), the lateral fissure or Sylvian cleft (or lateral sulcus in humans) are similar between both species and define similar regions.

The frontal lobe in *P. blainvillei* extends up to the entolateral sulcus, unlike in humans, where this lobe extends into the central sulcus (cruciate sulcus in *P. blainvillei*). However, the cruciate sulcus (central sulcus in humans) is responsible for defining the orbital lobe in this animal. The lobe of greater size and development in *P. blainvillei*, as well as in general odontoceti, is the parietal and temporal lobe (or temporo-parietal region), due to the great development of the auditory system (HOF et al., 2005; MARINO, 2007; OELSCHLAGER; OELSCHLAGER, 2002; OELSCHLAGER et al., 2010). In humans the frontal lobe is more prominent (KIERNAN, 2003; MACHADO, 2002).

The pattern of sulci and gyri of the parietal lobe in the telencephalon of *P. blainvillei* does not follow the pattern established in odontoceti, meaning for most species chosen in most of the studies on cetaceans, the *Tursiops truncatus* (bottlenose dolphin). Although the parietal lobe presents inferior lateral sulcus (ectosylvian sulcus), intermediate lateral sulcus (suprasylvian sulcus), superior lateral sulcus (ectolateral sulcus) and entolateral sulcus (paralimbic cleft), these do not concentrically envelop the lateral fissure (Sylvian cleft),

due to the non-verticalization of this fissure as reported in *Tursiops truncatus*. On the other hand, the lateral fissure (or Sylvian cleft) is quite similar to the lateral sulcus (or Sylvian) in humans, however the same pattern of sulcus tangent to this fissure in the parietal lobe is not verified in humans. Unlike in the human species, the pattern of sulcus in the parietal lobe is mostly perpendicular to the lateral sulcus and not tangential as noted in *P. blainvillei*.

The temporal lobe is highly developed in *P. blainvillei*, and does not show a characteristic pattern of sulci and gyri as in humans. However, its demarcation in relation to the occipital lobe resembles the demarcation in humans, not having a distinctive sulcus that defines them from one another. Furthermore, the occipital lobe is not present in all odontoceti, such as in the *Kogia sima* (dwarf sperm whale) (OELSCHLAGER et al., 2010).

Three major sulci mark the medial brain surface of *P. blainvillei*: the callosal sulcus (or esplenial), limbic sulcus (corresponding to the cingulate sulcus or supraspinal groove in humans) and the entolateral sulcus (paralimbic cleft). The first two sulci mentioned can also be observed in humans (KIERNAN, 2003; MACHADO, 2002). They demarcate the cingulate gyrus, which corresponds to the limbic lobe in *P. blainvillei*.

The presence of the calcarine sulcus has been reported in the medial brain surface in odontoceti by some authors (HOF et al., 2005; OELSCHLAGER; OELSCHLAGER, 2002) and by the present study, defining the lingual and oval lobules, the latter being part of the occipital region. Similarly, the calcarine sulcus defines the inferior portion of the cuneo in human species, an area belonging to the occipital lobe. However, it is not known if the region defined by the calcarine sulcus in cetaceans has the same function (vision) (KIERNAN, 2003; MACHADO, 2002) as in humans (OELSCHLAGER; OELSCHLAGER, 2002). Also, the vertical orientation of this sulcus in *P. blainvillei* differs completely from humans, as it has horizontal orientation.

The ventral surface of *P. blainvillei* telencephalon is divided into two parts, similar to humans; one belonging to the frontal lobe (orbital lobule); and another, much larger, belonging to the temporal lobe. However, the inferior frontal lobe portions in the human brain have structures related to rhynencephalon (olfactory bulb, olfactory tracts and the olfactory trine) (MACHADO, 2002). The presence of olfactory tubercles can be verified in the orbital lobule (frontal lobe) of *P. blainvillei*, although the total loss of the rostral olfactory structures and all accessory olfactory system is described in the literature (OELSCHLAGER; OELSCHLAGER, 2002). Similarly, there are descriptions of olfactory tubercles in *Kogia sima* (sperm whale) (MARINO et al., 2003a; OELSCHLAGER; OELSCHLAGER, 2002; OELSCHLAGER et al., 2010).

CONCLUSION

The encephalon of *P. blainvillei* differs from those in humans for being rostral-caudally shorter, rostrally tapered and caudally expanded, making it wider with a greater amount of grey than the human brain. The same brain lobes are observed in *P. blainvillei* and in humans. However, there are differences in their degree of development, possibly related to specific functions in each species such as a developed auditory system in cetaceans. Parietal and temporal lobes of *P. blainvillei* are larger than the other lobes, differing from the human species where the frontal lobe is more developed.

ACKNOWLEDGMENTS

To the BioPesca Project for donating the encephalons, to Felipe Montanari and Thiago Lezardo Unimonte's lab technicians and to Mariana Duarte Sutillo for the illustration of this research.

REFERENCES

- BERTA, A.; SUMICH, J. L.; KOVACS, K. M. **Marine mammals - evolutionary biology**. 2. ed. London: Elsevier, 2006.
- BERTOZZI, C. P. **Interação com a pesca: implicações na conservação da Toninha, *Pontoporia blainvillei* (Cetacea, Pontoporiidae) no litoral do estado de São Paulo, SP**. 2009. 189f. Tese de Doutorado. Universidade de São Paulo, 2009.
- BERTOZZI, C. P.; ZERBINI, A. N. Incidental mortality of franciscana, *Pontoporia blainvillei*, in the artisanal fishery of Praia Grande, São Paulo State, Brazil. **Lat. Am. J. Aquat. Mamm.**, v. 1, n. 1, p. 153-160, 2002.
- BERTOZZI, C. P. J. et al. Idade e comprimento de maturidade sexual para machos e fêmeas de toninha, *Pontoporia blainvillei* acidentalmente capturadas no estado de São Paulo. In: XIV Reunião de Trabalho de Especialistas em Mamíferos Aquáticos da América do Sul, 2010, Florianópolis. **Annais...** Florianópolis: Santa Catarina, 2010.
- COSTA, P. C. S.; BARBOSA, L. A.; SILVEIRA, L. S. Toninha (*Pontoporia blainvillei*). **JBCA - Jornal Brasileiro de Ciência animal**, v. 10, n.5, p.1-5, 2012.
- CRESPO, E.; HARRIS, G.; GONZALES, R. Group size and distribution range of the franciscana *Pontoporia blainvillei*. **Marine Mammal Science**, v. 14, p. 845-849, 1998.
- FOWLER, M. E.; CUBAS, Z. **Biology, medicine and surgery of the South American wild animals**. Iowa: Iowa State University Press, 2001. 536p.
- HETZEL, B.; LODI, L. **Baleias, botos e golfinhos: guia de identificação para o Brasil**. Rio de Janeiro: Nova Fronteira, 1993. 279p.
- HOF, P. R.; CHANIS, R.; MARINO, L. Cortical complexity in cetacean brains. **The Anatomical Record**, v. 287, p. 142-1152, 2005.
- IcMBIO (Instituto Chico Mendes de Conservação da Biodiversidade). **Lista oficial das espécies da fauna brasileira ameaçadas de extinção**. Diário oficial da união, 18 dez 2014. Disponível em: <www.icmbio.gov.br>. Acesso em 5 set. 2016.
- JEFFERSON, T. A.; LEATHERWOOD, S.; WEBBER, M. A. **Marine mammals of the world. FAO Species Identification Guide**. Rome:

United nations environment programme food and agriculture organization of the united nations. 1993. 320p.

KIERNAN, J. A. Topografia dos hemisférios cerebrais. In: **Neuroanatomia humana de Barr**. São Paulo: Editora Manole, 2003. p. 260-268.

MACHADO, A. 2002. Anatomia macroscópica do telencéfalo. In: **Neuroanatomia Funcional**. São Paulo: Editora Atheneu, 2002. p. 59-74.

MANGER, P. R. An examination of cetacean brain structure with a novel hypothesis correlating thermogenesis to the evolution of a big brain. **Biol. Rev.**, v. 81, p. 293-338, 2006.

MARINO, L. A comparison of encephalization between odontocete cetaceans and anthropoid primates. **Brain, Behavior and Evolution**, v. 51, p. 230-238, 1998.

MARINO, L. Brain size evolution. In: Perrin WF, Wursig B, Thewissen H. **Encyclopedia of marine mammals**. San Diego: Academic Press, 2002. p. 149-152.

MARINO, L. Cetacean Brain Evolution: Multiplication Generates Complexity. **International Journal of Comparative Psychology**, v.17, p. 1-16, 2004.

MARINO L. Cetacean brains: how aquatic are they? **The Anatomical Record**, v. 290, p. 694-700, 2007.

MARINO, L. et al. Cetaceans have complex brains for complex cognition. **PLoS. Biol.**, v. 5, p. 966-972, 2007.

MARINO, L.; MCSHEA, D. W.; UHEN, M. D. Origin and evolution of large brains in toothed whales. **The Anatomical Record**, v. 281A, p. 1247-1255, 2004a

MARINO, L. et al. Magnetic resonance images of the brain of a dwarf sperm whale (*Kogia simus*). **Journal of Anatomy**, v. 204, p. 57-76, 2003a.

MARINO, L. et al. Neuroanatomy of the Killer Whale (*Orcinus orca*) from magnetic resonance images. **The Anatomical Record**, v. 281, p.1256-1263, 2004b.

MARINO, L. et al. Anatomy and three-dimensional reconstruction of the brain of bottlenose dolphin (*Tursiops truncatus*) from magnetic resonance images. **The Anatomical Record**, v. 264, p. 397-414, 2001.

MARINO, L. et al. Reconstructing cetacean brain evolution using computed tomography. **The Anatomical Record**, v. 272B, p.107-117, 2003b.

MOREIRA, L. M.; SICILIANO, S. Northward extension range for *Pontoporia blainvillei*. In: Ninth Biennial Conference on the Biology of Marine Mammals, 48, 1991. **Anais...** Chicago: Illinois, 1991.

NETTO, R. F.; DI BENEDITTO, A. P. M. Interactions between fisheries and cetaceans in Espírito Santo State coast, southeastern Brazil. **Revista Brasileira de Zoociências**, v.10, p.55-63, 2008.

OELSCHLÄGER, H. H. A.; RIDGWAY, S. H.; KNAUTH, M. Cetacean brain evolution: dwarf sperm whale (*Kogia sima*) and common dolphin (*Delphinus delphis*) – An investigation with high-resolution 3D MRI. **Brain Behav Evo.**, v.75, p. 33-62, 2010.

OELSCHLÄGER, H. A. The dolphin brain – A challenge for synthetic neurobiology. **Brain Research Bulletin**, v. 75, p. 450-459, 2008.

OELSCHLÄGER, H. A.; OELSCHLÄGER, J. S. Brains. In: Perrin, W. F. Wursig, B.; Thewissen, H. **Encyclopedia of marine mammals**. San Diego: Academic Press, 2002. p. 133-149.

OTT, P. et al. Report of the group on fishery interactions. **The Latin American Journal of Aquatic Mammals**, v. 1, p. 55-64, 2002.

RIDGWAY, S. H.; BROWNSON, R. H. Relative brain sizes and cortical surface areas of odontocetes. **Acta Zoologica Fennica**, v. 172, p. 49-152, 1984.

SCHMIDEK, W. R.; CANTOS, G. A. Evolução do sistema nervoso, especialização hemisférica e plasticidade cerebral: um caminho ainda a ser percorrido. **Revista Pensamento Biocêntrico**, v. 10, p. 181-204, 2008.

SCHWERDTFEGGER, W. K.; OELSCHLÄGER, H. A.; STEPHAN, H. 1984. Quantitative neuroanatomy of the brain of the La Plata dolphin, *Pontoporia blainvillei*. **Anatomy and Embriology**, v. 170, p. 1-19, 1984.

SICILIANO, S. A toninha, *Pontoporia blainvillei*, nos estados do Rio de Janeiro e Espírito Santo, costa sudeste do Brasil: caracterização dos habitats e fatores de isolamento de populações. **Boletim do Museu Nacional, Série Zoologia**, v. 476, p. 1-15, 2002.