

TRAUMATIC SPINAL CORD INJURY WITH SCHIFF-SHERRINGTON POSTURE AND SPONTANEOUS RESOLUTION IN A DOG: MRI EVALUATION

[Trauma medular com postura de schiff-sherrington e resolução espontânea em um cão: avaliação com ressonância magnética]

Vinicius Gonzalez Peres Albernaz^{1*}, Isabella de Almeida Fabris², Bruna Ribeiro Paiva¹, Jeniffer Gabriela Figueroa Coris³, Juliany Gomes Quitzan⁴

¹ Médico Veterinário Residente, Departamento de Cirurgia e Anestesiologia Veterinária, Faculdade de Medicina Veterinária e Zootecnia – UNESP, Botucatu – SP.

² Aluna de Graduação, Medicina Veterinária, Faculdade de Medicina Veterinária e Zootecnia – UNESP, Botucatu – SP.

³ Programa de Aprendizagem e Treinamento, Departamento de Cirurgia e Anestesiologia Veterinária, Faculdade de Medicina Veterinária e Zootecnia – UNESP, Botucatu – SP.

⁴ Docente, Departamento de Cirurgia e Anestesiologia Veterinária, Faculdade de Medicina Veterinária e Zootecnia – UNESP, Botucatu – SP.

ABSTRACT – The Schiff-Sherrington phenomenon is an extensor hypertonicity of the forelimbs that occurs when there is a severe injury in the thoracolumbar segment. A 4-years-old, intact female, mixed breed dog, presented with vehicle trauma history followed by non-ambulatory paraparesis, extensor rigidity of forelimb and allodynia pain sensation. Superficial pain sensation was decreased. The treatment was based on unique dose of dexamethasone followed by oral administration of meloxicam, tramadol hydrochloride, dypirone, omeprazole and, poly vitamin complex. Low field magnetic resonance image (MRI) showed hyperintensity signal between T12 and T13 on T2-weighting image compatible with neuronal edema. In the day after, allodynia and extensor rigidity presented spontaneously resolution. At 10th day, return to voluntary ambulation without assistance. Schiff-Sherrington posture is usually associated with poor prognosis and grade V traumatic injury of the thoracolumbar spinal cord. We report a grade III traumatic spinal cord injury confirmed with MRI as only neuronal edema causing the posture. The Schiff-Sherrington posture often resolves spontaneously in 10-14 days, but neurological signs of trauma can persist. The conservative treatment proposed was efficient, promoting forelimb recovery on the day after and total recovery of motor function in 10 days.

Keywords: Canine; Acute; Extensor; Rigidity; Recover.

RESUMO – O fenômeno Schiff-Sherrington é a hipertonicidade extensores dos membros torácicos que ocorre quando há lesão severa do seguimento de medula espinhal toracolombar. Uma canina, fêmea, sem raça definida de 4 anos de idade foi apresentada após trauma por automóvel seguido de paraparesia não ambulatória, rigidez extensora dos membros torácicos e sensação dolorosa classificada como alodinia. A dor superficial estava diminuída. O tratamento se baseou na administração única de dexametasona seguida da prescrição de meloxicam, cloridrato de tramadol, dipirona, omeprazol e complexos vitamínicos. A ressonância magnética de baixo campo demonstrou hiperintensidade de sinal entre T12 e T13 nas sequencias ponderadas em T2, o que é compatível com edema neuronal. No dia seguinte, alodinia e a rigidez extensora apresentaram resolução espontânea. No 10º dia, houve retorno a deambulação voluntária sem assistência. A postura de Schiff-Sherrington está geralmente associada a prognóstico ruim e lesões traumáticas grau V da medula espinhal toracolombar. Relata-se uma lesão medular traumática grau III confirmada por ressonância magnética somente como edema neuronal levando à posição. A postura de Schiff-Sherrington frequentemente se resolve espontaneamente em 10-14 dias, mas sinais neurológicos podem persistir. O tratamento conservativo proposto foi eficiente, promovendo recuperação dos membros torácicos no dia seguinte e a recuperação total da função motora em 10 dias.

Palavras-Chave: Canino; Agudo; Extensor; Rigidez; Recuperação.

* Autor para correspondência. E-mail: vinicius.gp.albernaz@gmail.com

Recebido: 25 de abril de 2016.

Aceito para publicação: 19 de maio de 2016.

INTRODUCTION

The Schiff-Sherrington phenomenon is characterized by extensor hypertonicity of the forelimbs and flaccid hindlimbs (Park; White; Tieber, 2012). It is a common condition in dogs with thoracolumbar spinal cord injury (Bali et al., 2009). It occurs due to interruption of ascendant inhibitory influence of the borders cells on motor neurons of forelimbs. The main cause is acute injury, and severe compression of the thoracolumbar segment (Bali et al., 2009).

Acute spinal cord trauma has high incidence in veterinary medicine. They may be caused by patient-related condition or exogenous trauma, due to motor vehicle accidents, falls, physical aggressions and/or projectiles (Webb; Ngan; Fowler, 2010). Endogenous lesions are related to extrusion and protrusion of disc materials, pathological fractures, congenital anomalies or vertebral instability (Webb; Ngan; Fowler, 2010).

We report a case of automobile spinal cord trauma of the thoracolumbar spine, confirmed by MRI, causing Schiff-Sherrington posture with rapid spontaneous recovery in a dog.

CASE REPORT

A 4-years-old, intact female, mixed breed dog, weighting 23 kg was presented with 1-hour history of vehicle trauma. Owner related lateral recumbence and non-ambulatory paraparesis. No other pathologic change was promptly detected. According to owners, before the accident the animal was completely healthy, without any evidence of illness.

At physical examination no significant change was detected. On neurologic evaluation, we noted non-ambulatory paraparesis, with Schiff-Sherrington position (Figure 1). Patellar, cranial tibial, ischiatic and, gastrocnemius reflex found to be increased bilaterally with normal withdraw reflex. Superficial and deep pain perception was preserved, but the first was decreased. The cutaneous trunk muscle reflex was absent after L2. Deep palpation of spinal column revealed hyperesthesia in thoracolumbar transition. Although focal pain sensation, any stimulus in other body parts also elicited pain response (allodynia).

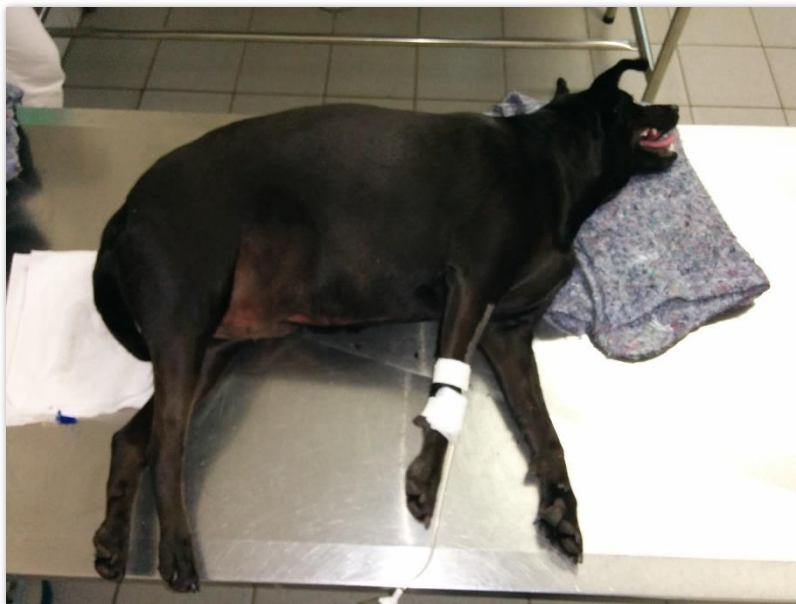

Figure 1. Canine one hour after trauma at lateral recumbence showing forelimb spasticity and flaccid to normal hindlimb. Additionally, dorsal flexion of neck can also be seen.

Thoracolumbar, lumbar and pelvic radiographies were performed. Only a mild intervertebral space decrease between T12-T13 was seen. No hematologic and biochemical change was found.

We administered dexamethasone $0,2\text{mg}\cdot\text{kg}^{-1}$ intramuscularly in unique dose. For home medication, we prescribed dypirone ($25\text{mg}\cdot\text{kg}^{-1}$ p.o

q12h for seven days), omeprazole ($1\text{mg}\cdot\text{kg}^{-1}$ p.o q24h for ten days), tramadol hydrochloride ($5\text{mg}\cdot\text{kg}^{-1}$ p.o for five days), vitamin complex (vitamin A 10.000UI, vitamin C 500mg, vitamin E 5mg, zinc 30mg, magnesium 10mg and selenium 50mcg, p.o, q24h for thirty days), vitamin B complex (thiamine nitrate 100mg, pyridoxine hydrochloride 100mg and cyanocobalamin

5000mcg p.o, q24h for thirty days) and meloxicam (0.1mg.kg⁻¹ p.o, q24h for seven days).

Low-field Magnetic Resonance Image (0.25 tesla) performed 24 hours after trauma showed hyperintensity sign in the spinal cord near the central channel, extending from T12 to T13's caudal epiphysis in T2-weighting, FLAIR and STIR sequences (Figure 1 A and B). No abnormality was

seen in T1-weight sequence (Figure 1 C). There was also mild degeneration and disc protrusion between T12-T13 and L1-L2. There was no evidence of fractures, dislocation or compressive disc herniation. Presumptive diagnosis was spinal cord edema caused by blunt trauma. No other therapeutic approach was added to therapy protocol after MRI results.

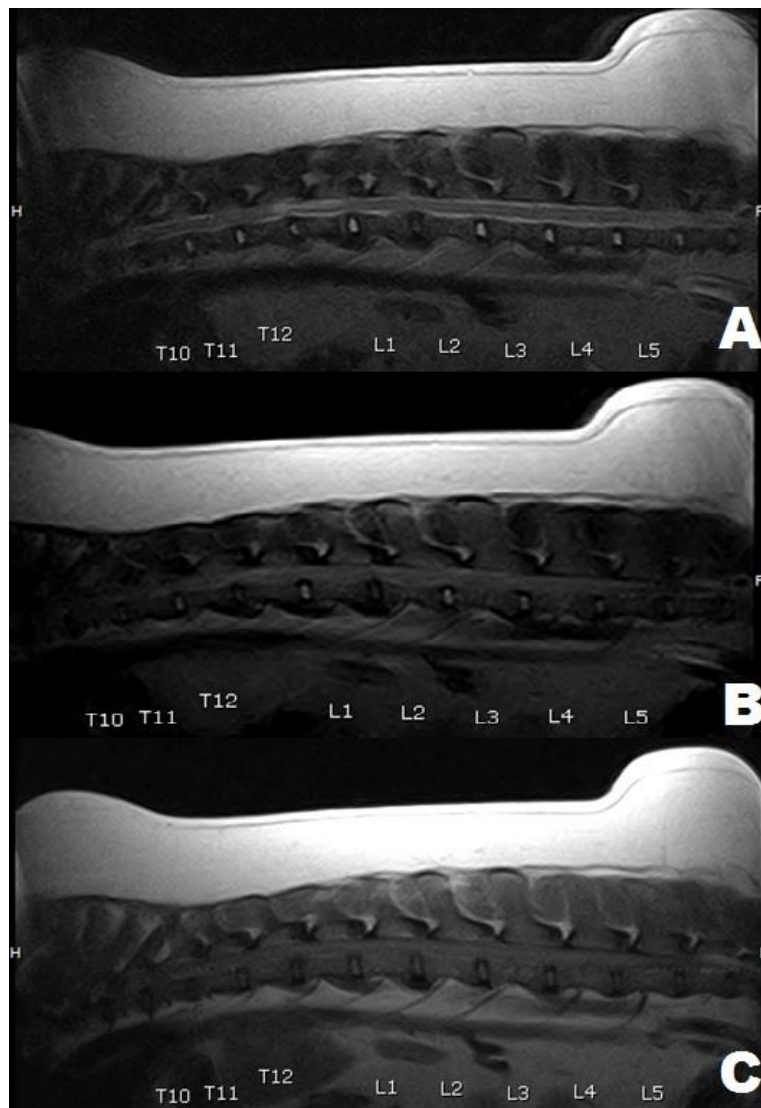


Figure 2. Low-field MRI of the thoracolumbar segments. (a) T2-weight image showing a one vertebra length intramedullary hyperintensity signal from T12 to caudal epiphysis of T13, suggesting spinal cord edema. (b) FLAIR sequence showing mild hyperintensity at the same segment (c) T1-weight image with no evidence of lesions.

In the day after MRI, spontaneous resolution of Schiff-Sherrington position occurred, and animal was able to stand up. At 5th day, allodynia and pain sensation were absent. Approximately 10 days after trauma, the animal returned to voluntary ambulate without assistance. From this moment, neurological

examination was normal and no other clinical sign was present.

DISCUSSION

Acute traumatic spinal cord injury can be classified into primary and secondary. Primary lesion is the

event that causes the initial spinal cord injury and are categorized as traumatic and non-traumatic events (Park; White; Tieber, 2012). On traumatic events, the main mechanical forces involved are compression, contusion, concussion, transection, laceration, flexion and/or, traction forces influence (Bergman; Lanz; Shell, 2000; Park; White; Tieber, 2012). Contusion and concussion occurs when spinal cord undergoes injury from external forces that damage vasculature and cause rapid acceleration and deceleration of parenchyma tissue, respectively (Vitale & Coates, 2007; Park; White; Tieber, 2012). Primary injury of this case report was caused by both contusion and concussion, causing spinal cord edema and hemorrhage. Other mechanical forces potentially evolved were not observed as well as no fracture, luxation or penetrating injury.

Secondary injury are the molecular and biochemical events following the primary event, caused by local changes like hemorrhage and hypoxia leading to a cascade of destructive events resulting in neuronal tissue death. (Bergman; Lanz; Shell, 2000; Park; White; Tieber, 2012). The goal of the conservative treatment is to limit and control the cascade events leading to cell death (Park; White; Tieber, 2012). In our case report, the patient did not show morphological changes, such as fractures or dislodgment, however, primary blunt and secondary injury causing neuronal edema was sufficient to cause severe clinical signs and Schiff-Sherrington position. The animal was graded III for medullary lesion, for non-ambulatory paraparesis with decreased, but preserved, superficial nociception (De LaHunta; Glass; Kent, 2009).

The presence of neurons at the dorsal aspect of the spinal cord lumbar segment (L1-L4), responsible for the tonic inhibition of the lower motor neuron present at the cervicothoracic tumescence explains the Schiff-Sherrington phenomenon (De LaHunta; Glass; Kent, 2009; Park; White; Tieber, 2012). When a thoracolumbar lesion occurs, the ascendant inhibitory stimuli is blocked, prevailing the tonic state of hyperextension of extensor muscles of the forelimb (De LaHunta; Glass; Kent, 2009). Nonetheless, postural reactions did not alter and voluntary movement are present, although rigid in the thoracic limb (De LaHunta; Glass; Kent, 2009). The presence of Schiff-Sherrington posture indicates a transversal severe lesion, but recovery can occur, since the condition itself does not imply in prognosis. (Vitale & Coates, 2007; Park; White; Tieber, 2012). The posture commonly presents spontaneous resolution within 10-14 days after lesion (De LaHunta; Glass; Kent, 2009). This paper reports a spinal cord blunt trauma at T12-T13 region without fracture or dislodgment with initial presentation of Schiff-Sherrington posture and

spontaneous full recovery with conservative treatment. Spinal cord edema was confirmed as the cause of clinical signs through low-field MRI.

In order to localize and detain medullary injuries, computerized tomography and MRI are considered gold-standard to evaluate spinal cord traumas (Park; White; Tieber, 2012). On MRI, T2-weight hyperintensity within spinal cord can be caused by a variety of forms of cellular injury, swelling, edema, necrosis and gliosis (Levine et al., 2009; Johnson et al., 2012). In our report, lesion was localized through neurological examination and confirmed by MRI. Due to spasticity and increased reflex of the hindlimb without forelimb signs, the lesion was on upper motor neuron of thoracolumbar segment. Few studies regarding the use of MRI in the evaluation of spinal trauma in small animals exist to date (Da Costa & Samii, 2010).

In a retrospective study comparing prognosis of Schiff-Sherrington position, only animals with elevated grades of injury (Grade IV and V) assumed the posture (Bali et al., 2009). Another prospective study of spinal cord trauma demonstrated obvious predominance of high grade injury associated with the phenomenon (Mendes & Arias, 2012). However, contradicting the previously published, the patient was in grade III of spinal cord injury and neurological examination combined with MRI exam did not suggest an extensive or serious injury. In both studies prognosis of patients with high grade lesions was death or euthanasia. Our patient survived to initial injury and demonstrated excellent response along time. Animals showing deep pain perception deficit tend to have poor to negative prognosis (Olby et al., 2003; Park; White; Tieber, 2012). Conservative treatment prescribed was efficient in treating blunt spinal cord trauma, so patient presented improvement signs of non-ambulatory state 24 hours after injury. In addition, 15 days after, the animal was completely ambulatory without human assistance. No sequelae were reported.

CONCLUSION

This case report reinforces the fact that even small medullary injuries with good prognosis can lead to Schiff-Sherrington syndrome and recover within some days spontaneously and aided by conservative treatment.

AGRADECIMENTOS

We would like to thank Professor Luiz Carlos Vulcano, DVM, PhD and Maria Cristina Reis Castiglioni, DVM, for MRI analysis and results.

REFERENCES

- BALL, M. S. et al. Comparative Study of Vertebral Fractures and Luxations in Dogs and Cats. **Veterinary and Comparative Orthopaedics and Traumatology**, v. 22, n. 1, p. 47-53, 2009.
- BERGMAN, R., LANZ, O., SHELL, L. Acute spinal cord trauma: mechanisms and clinical syndromes. **Veterinary Medicine**, v. 95, n. 1, p. 846-849, 2000
- DA COSTA, R. C., SAMII, V. F. Advanced imaging of the spine in small animals. **Veterinary Clinics of North America: Small Animal Practice**, v. 40, n. 5, p.765-790, 2010.
- DE LAHUNTA, A., GLASS, E. N., KENT, M. **Veterinary Neuroanatomy and Clinical Neurology**. 3. Ed., St Louis, W.B. Saunders, 2009. 504 p.
- JOHNSON, P. et al. Magnetic Resonance Imaging Characteristics of Suspected Vertebral Instability Associated with Fracture or Subluxation in Eleven Dogs. **Veterinary Radiology & Ultrasound**, v. 53, n. 5, p.552-559, 2012
- LEVINE, G. J. et al. Description and Repeatability of a Newly Developed Spinal Cord Injury Scale for Dogs. **Preventive Veterinary Medicine**, v. 89, n. 1-2, p.121-127, 2009.
- MENDES, D. S., ARIAS, M. V. B. Traumatismo da Medula Espinhal em Cães e Gatos: Estudo Prospectivo de 57 Casos. **Pesquisa Veterinária Brasileira**, v. 32, n. 12, p. 1304-1312, 2012.
- OLBY, N. et al. Long-Term Functional Outcome of Dogs with Severe Injuries of the Thoracolumbar Spinal Cord: 87 cases (1996-2001). **Journal of the American Veterinary Medical Association**, v. 222, n. 6, p. 762-768, 2003.
- PARK, E. H., WHITE, G. A., TIEBER, L. M. Mechanisms of Injury and Emergency Care of Acute Spinal Cord Injury in Dogs and Cats. **Journal of Veterinary Emergency and Critical Care**, v. 22, n. 2, p. 160-178, 2012.
- VITALE, C.; COATES, J. Acute Spinal Cord Injury. **Standards of Care: Emergency and Critical Care Medicine**, v. 9, n. 7, p. 1-11, 2007.
- WEBB, A. A., NGAN, S., FOWLER, D. Spinal Cord Injury II: Prognostic Indicators, Standards of Care, and Clinical Trials. **The Canadian Veterinary Journal**, v.51, n. 6, p. 598-604, 2010.