

Surgical access for diaphyseal osteosynthesis of long bones of the thoracic limb in *tamandua tetradactyla*

Acesso cirúrgico para osteossíntese diafisária de ossos longos do membro torácico em *Tamanduá tetradactyla*

Marcia Cristina Conceição da Costa¹ , Érika Branco² , Ana Rita de Lima^{2*} 

ABSTRACT: The reduction of habitats due to the advance of urban areas and human activities has a direct impact on the reduction of wild fauna, with a resulting increase in traumas due to animals being run over, fires, hunting, dog attacks and others. This had led to an increase in clinical-surgical consultations and practices in the veterinary routine. Seven preserved specimens were used for macroscopic description of the musculature and identification of surgical approaches for diaphyseal osteosynthesis of long bones of the thoracic limb of *Tamandua tetradactyla*. The suggested accesses were by approaches: craniomedial for the humerus, craniolateral for the radius, in turn, for the ulna caudolateral intervention is indicated. The goal of this information is to contribute with anatomical knowledge, which is crucial in enabling assertive choices in the clinical-surgical management of *T. tetradactyla*.

KEYWORDS: Xenarthra; surgery; lesser anteater; morphology; osteology.

RESUMO: A redução de habitats devido ao avanço das áreas urbanas e das atividades humanas tem impacto direto na redução da fauna silvestre, com consequente aumento de traumas por atropelamentos de animais, incêndios, caçadas, ataques de cães e outros. Isso levou a um aumento nas consultas e práticas clínico-cirúrgicas na rotina veterinária. Sete espécimes preservados foram utilizados para descrição macroscópica da musculatura e identificação de abordagens cirúrgicas para osteossíntese diafisária de ossos longos do membro torácico de *Tamandua tetradactyla*. Os acessos sugeridos foram pelas abordagens: cranio-medial para o úmero, craniolateral para o rádio, por sua vez, para a ulna está indicada a intervenção caudolateral. O objetivo dessas informações é contribuir com o conhecimento anatômico, fundamental para possibilitar escolhas assertivas no manejo clínico-cirúrgico do *T. tetradactyla*.

PALAVRAS-CHAVE: Xenarthra; cirurgia; tamanduá-mirim; morfologia; osteologia.

INTRODUCTION

The lesser anteater (*Tamandua tetradactyla*, Linnaeus, 1758) belongs to the Class Mammalia, Superorder Xenarthra, Order Pilosa, Suborder Vermilingua, Family Myrmecophagidae, Genus *Tamandua*. The Order Pilosa consists of anteaters and sloths (Medri *et al.*, 2011). In turn, the Myrmecophagidae Family is made up *Tamandua tetradactyla* together with *Myrmecophaga tridactyla* and *M. mexicana*, Linnaeus, 1758 (MACHADO *et al.*, 2008). The species is endemic to cis-andine America (Ohana *et al.*, 2015) and has been recorded east of the Andes, from the Guianas, through Venezuela, Colombia, down to northern

Argentina and Uruguay (Superina; Abba, 2010). In Brazil, it occurs in all biomes (Fonseca *et al.*, 1996; Paglia *et al.*, 2012).

The main characteristic of this species is the total absence of teeth and the presence of a long and conical nose that accommodates a vermiform tongue that is used to capture food. The ears are tiny, the eyes small and black, forelimbs strong and provided with claws protected by palmar support, which is the only means of defense and a tool for searching for food (Miranda, 2014).

The main threats identified for the taxon are habitat loss caused by fire, land conversion for agricultural activity,

¹Doutoranda (o) do Programa de Pós-graduação em Saúde e Produção Animal na Amazônia (PPGSPA) na Universidade Federal Rural da Amazônia (UFRA), Belém, Pará, Brasil.

²Docente do Instituto da Saúde e Produção Animal (ISPA) e do Programa de Pós-graduação em Saúde e Produção Animal na Amazônia (PPGSPA) na Universidade Federal Rural da Amazônia (UFRA), Belém, Pará, Brasil. Universidade Federal de Pelotas, Pelotas/RS, Brasil

*Corresponding author: Ana Rita de Lima, e-mail: arlimavet@gmail.com

Received: 05/28/2024

Accepted: 07/29/2024

predation by exotic species, deforestation, the increase in the road network and hunting (Aguiar; Fonseca, 2008; Noss *et al.* 2008). Such threats associated with inefficient wildlife conservation practices have generated an increase in the number of cases of routine veterinary care for wild animals that are victims of being run over, burns, hunting, dog attacks, and infectious diseases (Torres *et al.*, 2019).

There is a growing need to expand studies on anatomy, physiology, ecology, anesthesia, clinic and surgery of wild animals. This reflection is perceived daily in the search for knowledge and updating in diagnostic techniques by veterinarians, who seek an accurate prognosis and more appropriate treatment (Mackey *et al.*, 2008).

Studies on surgical access have already been described in domestic species, such as dogs (Latorre, 2012; Fossum, 2021; Piermattei; Flo; Decamp, 2016) as well as in wild animals, such as giant anteaters (Sesoko, 2012, Magalhães, 2022), Brown-throated sloths (Martins *et al.*, 2017), sloths (Lima *et al.*, 2019), black howler monkeys (PACHECO; PACHECO, 2021), Mandrills (Tong; Guiot, 2013) and Others.

Knowledge of the anatomical region that will be submitted to a surgical intervention is essential for successful surgical procedures (Relva, 2010). The theme addressed in this work arises from the need to expand knowledge about the species, the morphological description of the musculature that makes up the forelimb and the performance of a comparative analysis with other domestic or wild species already described.

This work aims to expand the view on *Tamandua tetradactyla* and generate knowledge that will be used in the medical and surgical care of wild animals, providing information for performing the most appropriate surgical access for diaphyseal osteosynthesis of long bones of the forelimb, which will promote assertive therapy of bone trauma in these animals and collaborate towards with the conservation and well-being of this species.

MATERIAL AND METHODS

Macroscopic Analysis

Seven corpses of male and female *Tamandua tetradactyla* were selected and analyzed, composed of one juvenile and six adults of different ages. The animals were donated by the Bauxite Mine located in Paragominas - Pará. They had died due to natural and/or human-induced causes and were donated to the Animal Morphological Research Laboratory (LaPMA) under authorization SEMA-PA No. 455/2009 and No. 522/2009, and SISBIO No. 23401-5.

The animals were fixed in a 10% formaldehyde aqueous solution through intramuscular and body cavity infusions and were kept submerged in the solution for a minimum period of seven days before dissection. To better distinguish between the samples, the animals were identified as anteater 1 (A1),

anteater 2 (A2), anteater 3 (A3), anteater 4 (A4), anteater 5 (A5), anteater 6 (A6) and anteater 7 (A7).

Bilateral dissection of the thoracic limbs was performed with skin reflection, identification of the arm and forearm muscles through their insertion and function in the limbs, and also of the vessels and nerves, the incision planes that departed from the skin and subcutaneous tissue. In six animals (A1, A2, A3, A4, A5 and A6) the skin of the thoracic region was sectioned and reflected to better visualize this region. The incisions were made from the cartilage of the manubrium to the xiphoid process, followed by the removal of the forelimbs. and identification of the bilateral musculature of the forelimb of specimens A2, A3, A4, A5 and A6.

Additionally, in A1, through the dissection performed in the carotid artery, injection of Neoprene latex dyed in red was administered, to identify the arterial vascularization of the thoracic limb; in A6 and A7, simulations of surgical accesses to the humeral, radial and ulnar. All structures were thoroughly analyzed, identified and photographed in order to document the results. All nomenclature adopted was based on the Veterinary Anatomical Nomenclature (International Committee on Veterinary Gross Anatomical Nomenclature, 2017).

RESULTS

Macroscopic Analysis

The previously undescribed musculature of *T. tetradactyla* was robust, especially the arm muscles. The following muscles were identified in the lateral view: supraspinatus, teres major, tensor fasciae antebrachii, triceps brachii long head, triceps brachii lateral head, deltoid scapular part, deltoid acromial portion, anconeus, infraspinatus and teres minor (Figure 1). It was observed that the deltoid muscle is divided into an acromial portion, which originates from the acromion and inserts into the lateral epicondyle of the humerus, and a scapular portion, which originates from the spine of the scapula and inserts into the deltoid tuberosity.

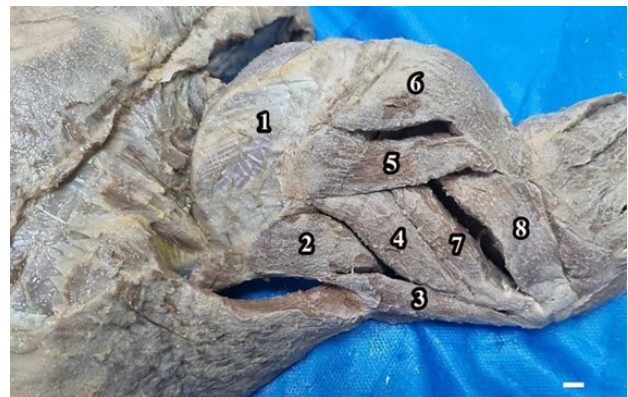


Figure 1. Photomacrograph lateral view of the right arm of *T. tetradactyla* (A2), demonstrating the muscles: supraspinatus (1), teres major (2), forearm fascia tensor (3), triceps brachii long head (4), deltoid scapular part (5), deltoid acromial part (6), triceps brachii lateral head (7), anconeus (8). Scale bar: 1cm.

The *M. triceps brachii* has three heads: long, lateral and medial; the long and lateral heads were observed laterally. These and have a lateral origin in the humerus and are inserted in the olecranon. The medial head is only visualized in the medial view of the arm, in which its origin is found in the middle third of the humerus and insertion also in the olecranon. The *M. supraspinatus* originates on the spine of the scapula and has the greater tubercle of the humerus as its insertion site. *M. tensor fascia antebrachii* is a continuation of *M. latissimus dorsi* that runs caudally to the caudal border of the scapula and inserts into the olecranon, and *M. anconeus* originates from the caudal part of the olecranon and inserts into the proximal third of the ulna.

In the lateral view of the forearm, the following muscles were identified: lateral digital extensor, carpi ulnar extensor, common digital extensor, carpi radialis extensor, superficial head brachioradialis, deep head brachioradialis, index extensor and supinator (Figure 2). As for muscle origins and insertions, it was found that the lateral digital extensor, carpi ulnar extensor, common digital extensor and carpi radialis extensor originate on the lateral epicondyle of the humerus and insert on the fourth metacarpal, on the palmar surface of the hand, on the proximal phalanges and distal row of carpals dorsally to the hand, respectively.

It was observed that the *M. brachioradialis* has two heads, superficial and deep, originating laterally in the distal third of the humerus and inserting in the final third of the radius, while the extensor index originates in the proximal third of the ulna and its insertion tendon is divided into two branches, the medial branch with insertion on the dorsal surface of the distal phalanx of the first finger and the lateral branch with insertion on the dorsal surface of the phalanx. Finally, the *M. supinator* originates in the lateral epicondyle of the humerus and inserts in the proximal third of the radius.

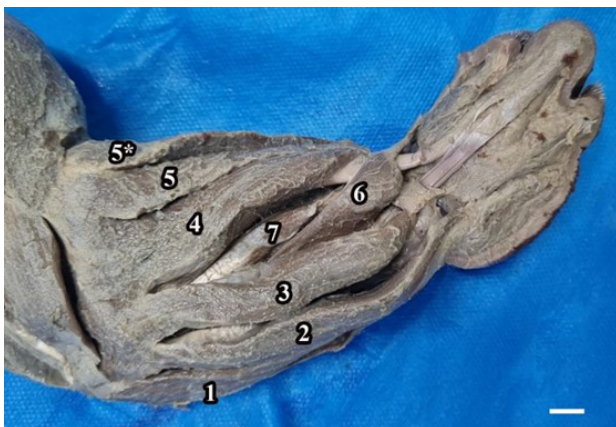


Figure 2. Photomicrograph of the lateral view of the right forearm of *T. tetradactyla* (A2), demonstrating the muscles: deep digital flexor (1), carpi ulnaris extensor (2), common digital extensor (3), carpi radialis extensor (4), deep head brachioradialis (5), superficial head brachioradialis (5*), extensor indicis (6) and supinator (7). Scale bar: 1 cm.

In the medial view of the arm, the following muscles were identified: subscapularis, latissimus dorsi, teres major, tensor fasciae antebrachii, triceps brachii long head, triceps brachii medial head, anconeus epitrochlearis, deltoid acromial portion, biceps brachii long head, biceps brachii short head (Figure 3). Next, the origin and insertion of the musculature identified were verified with the *M. subscapularis* originating in the medial margin of the scapula and inserted in the greater tubercle of the humerus. Additionally, the *M. anconeus epitrochlearis* that originated in the caudal part was visualized for the olecranon, as well as its insertion in the anconeal process. It was also found that the *M. biceps brachii* has two heads, the long one originating in the coracoid process of the scapula and inserted in the proximal third of the ulna, and the short one originating in the middle third of the humerus and inserting in the third proximal to the radius.

In the medial view of the forearm, the following muscles were identified: superficial digital flexor, superficial head brachioradialis, deep digital flexor, carpi radialis flexor, teres pronator, long head biceps, short head biceps, coracobrachialis and triceps (Figure 4). The origin and insertion of these was also detailed, and it was noted that the *Mm. Superficial digital flexor* and *deep digital flexor* originate in the medial epicondyle of the humerus, when inserted the superficial inserts into phalanges III and IV, while the deep inserts into phalanx II.

Furthermore, the *M. flexor carpi radialis* originates in the lateral epicondyle of the humerus and inserts in the distal row of the carpi dorsally to the hand while the *M. pronator teres* originates in the medial epicondyle of the humerus and

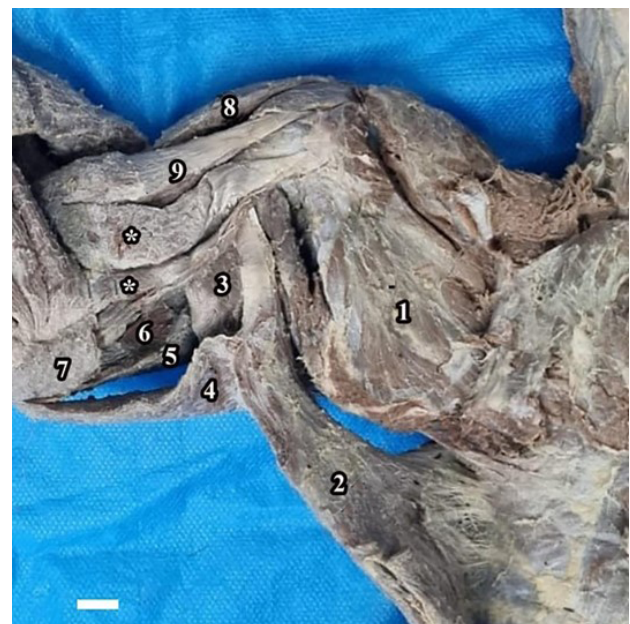

Figure 3. Photomicrograph medial view of the right arm of *T. tetradactyla* (A2), demonstrating the muscles: subscapularis (1), latissimus dorsi (2), teres major (3), forearm fascia tensor (4), triceps brachii long head (5), triceps brachii medial head (6), anconeus epitrochlearis (7), deltoid acromial part (8), biceps brachii short head (9), biceps brachii long head (*). Scale bar: 1 cm.

inserts in the distal third of the radius. Finally, the *M. coracobrachialis* originates on the coracoid process of the scapula and inserts on the middle third of the humerus.

Rete Mirabile of *Tamandua Tetradactyla*

After previous bilateral dissection and identification of the musculature of the thoracic limbs of animal A1, which had previously been injected with latex, the superficial and deep pectoral muscles were sectioned, divulsed and reflected to expose and identify the branches of the arm and forearm of the brachial plexus and *rete mirabile* (Figure 5). The complex arterial vascular network was visualized in the thoracic limb medially inserting in the muscles: superficial head brachioradialis, teres pronator, deep digital flexor, carpi radialis flexor.

Surgical Access for Humeral Shaft in *Tamandua Tetradactyla*

From analysis of the anatomical findings, it is suggested that the best surgical access to the humeral diaphysis is cranially through the medial surface, since robust muscle groups are found on the lateral surface and are difficult to divulse.

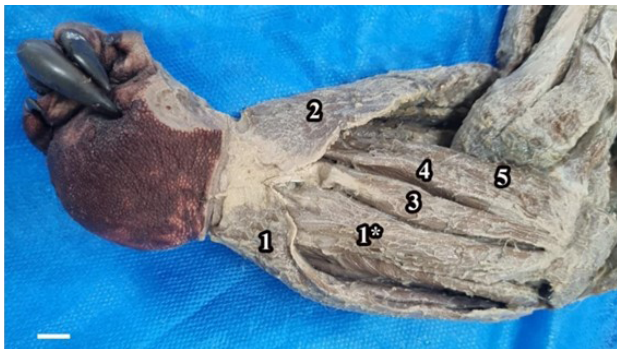

Figure 4. Photomacrograph of the medial view of the right forearm of *T. tetradactyla* (A2), demonstrating the muscles: superficial digital flexor (1 and 1*); brachioradialis superficial head (2); deep digital flexor (3); flexor carpi radialis (4); round pronator (5). Scale bar: 1 cm.

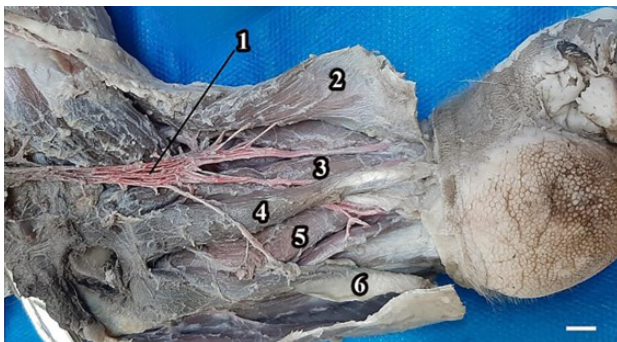


Figure 5. Photomacrograph of the medial view of the forearm of *T. tetradactyla* (A1), demonstrating the *rete mirabile* (1) inserting into the muscles: brachioradialis superficial head (2), pronator teres (3), flexor carpi radialis (4), deep digital flexor (5), superficial digital flexor (6). Scale bar: 1 cm.

For surgical access, the specimen was positioned with the aid of a surgical drape in dorsal decubitus, and a skin and fascia incision were made from the proximal epiphysis to the medial epicondyle distally (Figure 6A). Subsequently, the biceps brachii short head and long head muscles were identified and divulsed (Figure 6B), to expose the proximal portion of the humerus. The *M. biceps brachii* short head was retracted cranially and the *M. biceps brachii* long head caudally, so as to enable visualization of the proximal diaphyseal surface of the humerus (Figure 6C).

Surgical Access for Diaphysis of the Radius in *Tamandua Tetradactyla*

For access to the radial diaphysis, it is suggested that the best approach is through the cranial face, laterally, since the *rete mirabile* of the forelimb of the specimen is found on the medial face. For surgical access, the animal was positioned in dorsal decubitus using a surgical chute and a skin and fascia incision was made from the proximal epiphysis of the radius to the distal middle third of the limb, distally (Figure 7A). Subsequently, the extensor indicis and supinator muscles (Figure 7B) were identified and divulsed, the *M. supinator* was

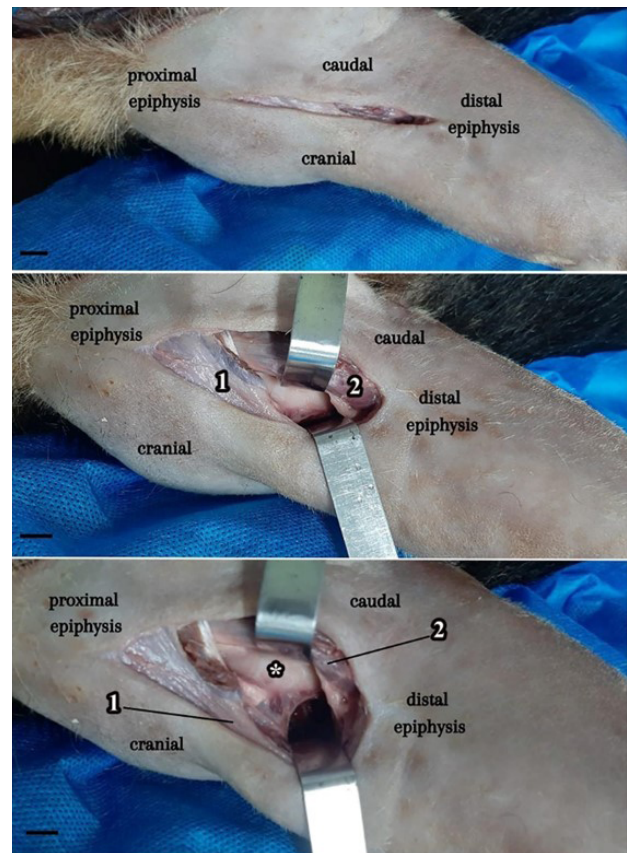


Figure 6. A - Skin and fascia incision in the medial approach of the right forelimb of *T. tetradactyla*. B - Identification and description of the short head (1) and long head (2) biceps brachii muscles; C - Exposure of the humeral shaft (1), biceps brachii short head (2) and biceps brachii long head (3) muscles. Scale bar: 1 cm.

retracted cranially and the *M. extensor indicis* caudally, thus obtaining a view of the diaphysis of the radius (Figure 7C).

Surgical Access to the Ulnar Shaft in *Tamandua Tetractyla*

The best approach for surgical access to the ulnar diaphysis is caudally from the lateral face, since the *rete mirabile* of the forelimb of the specimen is found on the medial face. The animal was positioned in dorsal decubitus with the aid of a surgical trough and a skin and fascia incision was made distally from the proximal epiphysis to the tuberosity of the crest of the ulna (Figure 8A). Subsequently, the extensor carpi ulnaris and the common digital extensor muscles were identified and divulsed (Figure 8B), the common digital extensor muscle was retracted cranially and the extensor carpi ulnaris caudally, thus obtaining a view of the diaphysis of the ulna (Figure 8C).

DISCUSSION

Tamandua tetractyla presented anatomical particularities in the forelimb that differ from those of domestic animals, species of Xenarthras, such as Linnaeus's two-toed sloth and the brown-throated sloth (Lima *et al.*, 2019; Silva *et al.*, 2021), and other arboreal species such as primates, due to the high muscular development. However, they resemble the characteristics

of *Tamandua* sp., the giant anteater (Magalhães, 2022; Sesoko, 2012; Taylor, 1978).

The musculature of the thoracic limb, arm and forearm have the general function of flexion and extension of the forelimbs (KARDONG, 2010), essential movements for *T. tetractyla*, as they favor traction with the claws in feeding and defense. As for the muscular development of the arm and forearm of the species studied, robust muscle groups were observed in the arm and well-developed musculature in the forearm, like the giant anteater, while in the brown-throated sloth the arm has less muscle development in relation to the forearm musculature (Diniz *et al.*, 2018).

In the arm of *T. tetractyla*, the triceps brachii muscle had three heads, lateral, long and medial, as occurs in giant anteaters, brown-throated sloths, capuchin monkeys, dogs, horses, cattle, pigs and rats (Diniz *et al.*, 2018; Dyce, 2019; Greene, 1955; König, 2021; Lima *et al.*, 2017; Magalhães, 2022). This is in contrast with the night monkey, which only has two heads of the triceps brachii muscle, the long and the medial, and also the domestic dog and wild dogs, which have one more head, the accessory (Dyce, 2019; Rodrigues *et al.*, 2013).

In the forearm, the brachioradialis muscle, responsible for the supination movement, in *T. tetractyla* presented two heads, superficial and deep, unlike the form that occurs in giant anteaters, brown-throated sloths, night monkeys,

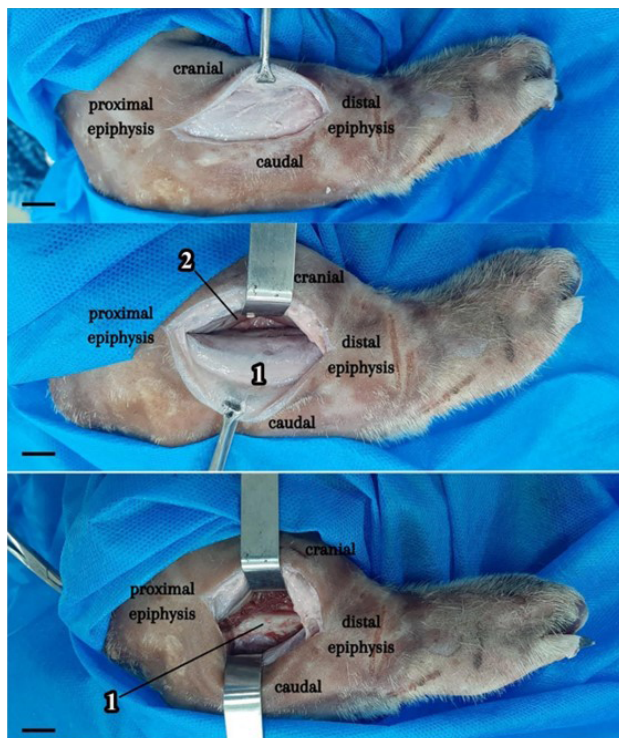


Figure 7. A - Skin incision by craniolateral approach to the right radius of *T. tetractyla* and visualization of the fascia. B - Identification, divulsion and reflection of the extensor indicis (1) and supinator (2) muscles. C - Exposure of the radial diaphysis (1). Scale bar: 1 cm.

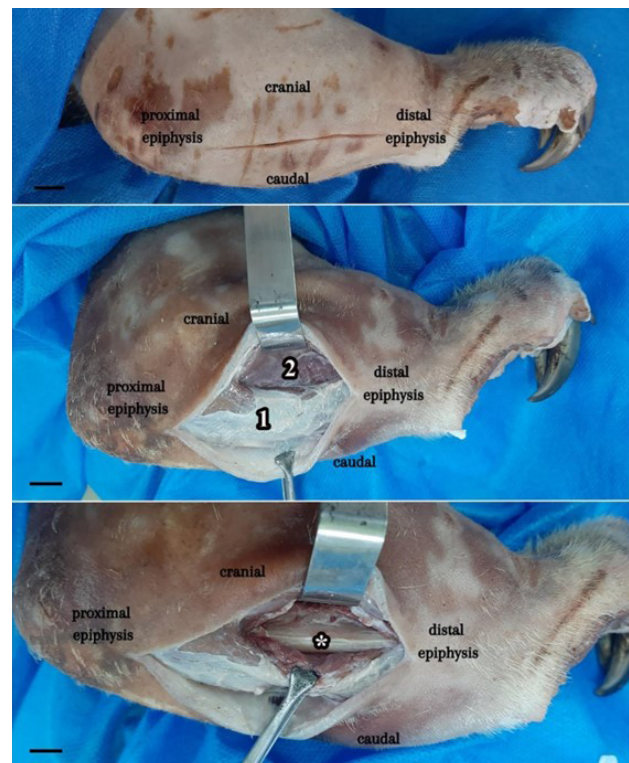


Figure 8. A - Cutaneous incision by lateral approach to the right ulna of *T. tetractyla*. B - Identification and divulsion of the extensor carpi ulnaris (1) and common digital extensor muscles (2); C - Exposure of the ulnar diaphysis (*). Scale bar: 1 cm.

dogs and cats, which have the brachioradialis muscle without heads (Diniz *et al.*, 2018; Dyce, 2019; Lima *et al.*, 2017; Magalhães, 2022; Sesoko, 2012).

In addition, in *T. tetradactyla* some anatomical variations stand out, such as the epitocleo-anconeus muscle and the double ramification of the tendon at the insertion of the extensor indicis muscle, which is divided into a medial branch and insertion into the dorsal face of the distal phalanx of the first finger and a lateral branch and insertion on the dorsal face of the phalanx, which favor greater breadth in the movement of the claws, which are essential for capturing food and for arboreal habits.

In general, the muscles that compose the arm and forearm of *T. tetradactyla* are the same as those found in domestic species and Xenarthras (Diniz *et al.*, 2018; Dyce, 2019; König, 2021; Magalhães, 2022; Martins *et al.*, 2017; Sesoko, 2012). However, through the presence of some distinct muscles we suggest that these are anatomical variations between the different species, these being any escape from what is more common, without prejudice to functionality (Thompson *et al.*, 1988).

For surgical access to the humeral diaphysis in *T. tetradactyla*, we determined that the best visualization is cranially through the medial face, with the divulsion of the biceps brachii muscles long head and short head. The same access is reported in giant anteaters, as the humerus has structures on the craniolateral surface that make this approach difficult (Sesoko, 2012). In black howler monkeys and brown-throated sloths, unlike the species studied, the lateral approach is reported (Martins *et al.*, 2017; Pacheco; Pacheco, 2021). With dogs, access occurs craniolaterally with the rebound of the Mm. brachiocephalic and superficial pectoralis cranially as well as the M. brachial caudally (Fossum, 2021; Latorre, 2012).

Thus, we observed that the robust musculature of the arm laterally was a decisive factor in choosing the medial approach, since the great development of the triceps brachii long head and triceps brachii lateral head muscles, made it difficult to divulse and access the humeral diaphysis. It is worth mentioning the specialization of the teres major muscle, which allows a great capacity for shoulder retraction, unlike what occurs in other mammals, as well as providing caudal rotation of the entire limb, which demonstrates its usefulness in climbing, attacking insect nests and in defensive behavior (Sesoko, 2012; Taylor, 1978).

Furthermore, we determined that the surgical access to the diaphysis of the radius in *T. tetradactyla* is performed laterally through the cranial face; due to the presence of the *rete mirabile*, the medial approach is not indicated, since vascularization is closely related to the muscles adjacent to the bone. The same approach is also reported in arboreal royal sloth and in Linnaeus's two-toed sloth species (Lima *et al.*, 2019; Martins *et al.*, 2017), as well as in mandrills (Tong; Guiot, 2013).

With dogs it is recommended to make the incision on the craniomedial surface, as the radius is more superficial in

this region and does not have muscle coverage, in addition to being easily palpated, which allows exposure with minimal bleeding, but the craniolateral access is also performed because it provides access to the proximal shaft of the radius with simultaneous access to the shaft of the ulna (Johnson, 2022; Latorre, 2012; Piermattei; Flo; Decamp, 2016). The incision on the craniomedial surface is recommended to giant anteaters, surgical access to the diaphysis of the radius can be performed laterally or medially (Magalhães, 2022).

Surgical access to the ulnar diaphysis in *T. tetradactyla* was determined by the lateral face, caudally, in which it is possible to palpate the bone, serving as a guide for the skin and fascia incision, followed by identification and divulsion of the Mm. common digital extensor and extensor carpi ulnaris. In dogs, access to the proximal ulnar shaft is performed on the caudal edge, from the tuberosity of the olecranon to the middle third of the forearm, until reaching the ulnar styloid apophysis, which is palpable (Latorre, 2012). In brown-throated sloths and Linnaeus's two-toed sloths, the same access is performed through the caudal approach to the bone, releasing the fixation of the flexor carpi ulnaris muscle (Lima *et al.*, 2019; Martins *et al.*, 2017). In giant anteaters, there are more reports so far on the aforementioned issue.

The presence of the *rete mirabile* on the medial face of the limb, previously undescribed in the species, had a direct impact on the suggestion of surgical accesses to the radial and ulnar diaphysis, since the complex vascularization inserts and irrigates several muscles, these being: brachioradialis superficial head, pronator teres, flexor digitalis profundus, flexor carpi radialis. The complex vascular network is highly developed in arboreal mammals and is called the "muscle bundle" (O'dea, 1990); among its functions is to act as a blood reservoir and storage to prevent blood stasis during prolonged muscle contraction (Adam, 1999).

In Xenarthras, Fernandes (2021) described the *rete mirabile* in sloths with a medial location on the forelimb, originating in the brachial artery and branching out in the distal portion, passing through the supratrochlear foramen, in order to irrigate the arm muscles. In the Mexican Tamandua, the *rete mirabile* appeared after a branching of the superficial antebrachial artery, divided into two branches, lateral and medial, and the distal ends of both arterial plexuses of the forearm anastomosed towards the back of the hand (Polania-Guzmán; Vélez-García, 2019). As for armadillos, in them the aforementioned vascularization is present in the tail, a site that facilitates and accelerates venipuncture (Luaces *et al.*, 2011).

Finally, through the morphological analysis of the forelimb of *T. tetradactyla*, we observed that the development and modification of the muscles, as well as the presence of the *rete mirabile*, directly influenced the choice of surgical approaches to the humeral, radial and ulnar diaphysis. Therefore, it is important to consider anatomical variations when performing clinical procedures and suggesting assertive surgical approaches in the growing care of wild animals.

REFERENCES

- ADAM, J. P. Mammalian Species: *Choloepus didactylus*. **American Society of Mammalogists**. n. 621, p. 1-8, 1999.
- AGUIAR, J. M.; FONSECA, G. A. B. 2008. Conservation status of the Xenarthra. Pp. 215–231. In: VIZCAÍNO S. F.; LOUGHRY W. J. (eds.). **The Biology of the Xenarthra**. University Press of Florida. 370 p.
- DINIZ, J. A. R. A. *et al.* Descrição anatômica dos músculos do membro torácico da preguiça-comum (*Bradypus variegatus*). **Acta Scientiae Veterinariae**, v. 46, p. 1601, 2018.
- DYCE, K. M. *et al.* 2019. **Tratado de Anatomia Veterinária**. 5ª Edição. Rio de Janeiro-RJ. Elsevier Editora Ltda. p. 184-190.
- FERNANDES, N. C. F. *et al.* **Ramos aórticos e rete mirabile dos membros locomotores de *Choloepus didactylus***. Tese de Doutorado. UFRA/Campus Belém. 2021.
- FONSECA, G. A. B. *et al.* **Lista anotada dos mamíferos do Brasil. Occasional Papers in Conservation Biology**, v. 4, p. 1-38. In: OHANA, J.A.B. *et al.* Avaliação do Risco de Extinção de *Tamandua tetradactyla* (Linnaeus, 1758) no Brasil. Avaliação do risco de extinção de Xenartros brasileiros. Brasília, DF: ICMBio. 1996.
- FOSSUM, T. W. 2021. **Cirurgia de pequenos animais**. 5ª Edição. Rio de Janeiro: Elsevier. p. 3177-3179.
- GREENE, E. C. **Anatomy of the Rat**. New York: Hafner Publishing, 370p. 1955. In: LIMA, A. R. *et al.* Miologia comparada do membro torácico de macaco-prego e macaco-da-noite. **Acta sci. vet.** (Online), p. 1-8. 2017.
- INTERNATIONAL COMMITTEE ON VETERINARY GROSS ANATOMICAL NOMENCLATURE. **Nomina anatomica veterinaria**. WAVA. 2017.
- JOHNSON, A. L. Management of Specific Fractures. In: FOSSUM, T. W. **Small Animal Surgery**. 5ª Edição. St. Louis: Elsevier, cap. 33, p. 1106-1214. 2022.
- KARDONG, K. V. 2010. **Vertebrados Anatomia Comparada, Função e Evolução**. 5ª Edição. São Paulo: Rocca, p. 439-485.
- KÖNIG, H. E.; LIEBICH, H-G. 2021. **Anatomia dos Animais Domésticos**: Texto e Atlas Colorido. Artmed Editora. p. 196-216.
- LATORRE, R. 2012. **Atlas de ortopedia em cães e gatos**: anatomia e abordagens cirúrgicas de ossos e articulações. São Paulo: Medvet. p. 43-89.
- LIMA, A. L. S. N. *et al.* **Descrição de acesso cirúrgico para osteossíntese de braço e antebraço da preguiça-real (*Choloepus didactylus* Linnaeus, 1758)**. Trabalho de Conclusão de Curso. UFRA/Campus Belém. 2019.
- LIMA, A. R. *et al.* Miologia comparada do membro torácico de macaco-prego e macaco-da-noite. **Acta sci. vet.** (Online), p. 1-8. 2017.
- LUACES, J. P. *et al.* The rete mirabile of the tail, an effective site for sampling sterile blood from armadillos (Dasypodidae, Xenarthra). **Italian Journal of Zoology**, 78, p. 63-69. 2011.
- MACHADO, A. B. *et al.* 2008. **Livro vermelho da fauna brasileira ameaçada de extinção**, 1ª Edição. Brasília, DF: MMA; Belo Horizonte, MG: Fundação Biodiversitas, v. 2. p. 2008.
- MACKEY, E. B. *et al.* Clinical technique: application of computed tomography in zoological medicine. **Journal of exotic pet medicine**, v. 17, n. 3, p. 198-209. 2008.
- MAGALHÃES, T. V. **Descrição de acessos cirúrgicos e corredores seguros do membro torácico, por meio de estudo anatômico da musculatura de tamanduá-bandeira (*Myrmecophaga tridactyla*)**. Dissertação de Mestrado. UNESP/Campus Jaboticabal. 2022.
- MARTINS, D. M. *et al.* **Determinação de acesso cirúrgico para osteossíntese em membro torácico de *Bradypus variegatus***. Tese de Doutorado. Universidade Federal Rural da Amazônia. 2017.
- MEDRI, I. M. *et al.* Ordem pilosa. **Mamíferos do Brasil**, v. 2, p. 91-106, 2011.
- MIRANDA, F. Cingulata (Tatus) e pilosa (Preguiças e Tamanduás). In: CUBAS, Z. S. *et al.* **Tratado de animais selvagens**: Medicina Veterinária. São Paulo: Roca, cap. 33, p. 793-804. 2014.
- NOSS, A. J. *et al.* **Exploitation of xenarthrans by the Guarani-Isoseño indigenous people of the Bolivian Chaco: comparisons with hunting by other indigenous groups in Latin America, and implications for conservation**. p. 244–254. In: VIZCAÍNO, S. F.; LOUGHRY, W. J. (eds.), **The Biology of the Xenarthra**. University Press of Florida, Gainesville. p. 370. In: OHANA, J. A. B. *et al.* Avaliação do Risco de Extinção de *Tamandua tetradactyla* (Linnaeus, 1758) no Brasil. Avaliação do risco de extinção de Xenartros brasileiros. Brasília, DF: ICMBio. 2008.
- O'DEA, J. D. The mammalian rete mirabile and oxygen availability. **Comparative Biochemistry and Physiology**. v. 95A, n. 1, p. 23-25. 1990.
- OHANA, J. A. B. *et al.* Avaliação do Risco de Extinção de *Tamandua tetradactyla* (Linnaeus, 1758) no Brasil. **Avaliação do risco de extinção de Xenartros brasileiros**. Brasília, DF: ICMBio. 2015.
- PACHECO, L.; PACHECO, K. O. M. Osteossíntese de úmero com a utilização de placa e pino intramedular para estabilização de fratura em um filhote de bugio preto. **Veterinária Notícias**, v. 27, n. 2, p. 60-71. 2021.
- PAGLIA, A. P. *et al.* Lista anotada dos mamíferos do Brasil. 2ª Edição. **Occasional Papers in Conservation Biology**, 6: 1-76. In: OHANA, J. A. B. *et al.* Avaliação do Risco de Extinção de *Tamandua tetradactyla* (Linnaeus, 1758) no Brasil. Avaliação do risco de extinção de Xenartros brasileiros. Brasília, DF: ICMBio. 2012.
- PIERMATTEI, D. L.; FLO, G. L.; DECAMP, C. E. **Brinker, Piermattei & Flo's handbook of small animal orthopaedics and fracture repair**. (5th edn). Piermattei DL, Flo GL, DeCamp (eds). Philadelphia, Saunders, p. 245-321. 2016.
- POLANIA-GUZMÁN, P. V.; VÉLEZ-GARCÍA, J. F. Gross anatomical adaptations of the craniolateral forearm muscles in *Tamandua mexicana* (Xenarthra: Myrmecophagidae): development of accessory muscles and rete mirabile for its arterial supply. **Heliyon**, v. 5, n. 8. 2019.
- RELVA, C. L. **Bases anatômicas para os principais acessos cirúrgicos ao membro torácico do cão**. Dissertação (Mestrado). Universidade de Trás-os-montes e Alto Douro, Vila Real. 2010.

RODRIGUES, R. G. A. *et al.* Descrição dos músculos do ombro e braço do cachorro do mato (*Cerdocyon thous*). **Revista Científica Eletrônica de Medicina Veterinária**, v. 3, n. 1, p. 138-145. 2013.

SESOKO, N. F. **Estudo anatômico e imaginológico do braço e da coxa em tamanduá-bandeira (*Myrmecophaga tridactyla*-Linnaeus, 1758) para a determinação de acesso cirúrgico.** Dissertação de Mestrado. UNESP. 2012.

SILVA, D. B. *et al.* Aspectos anatômicos dos músculos do antebraço de *Myrmecophaga tridactyla*. **Acta Veterinaria Brasilica**, v. 15, n. 1, p. 60-65. 2021.

SUPERINA, M.; ABBA, A. M. The 2010 Anteater Red List Assessment. **Edetata**, v. 11, p. 96-115. 2010.

TAYLOR, B. K. The Anatomy of the forelimb in the anteater (*Tamandua*) and its functional implications. **Journal of Morphology**, v. 157, n. 3, p. 347-368. 1978.

THOMPSON, S. A. *et al.* **Compedium of human anatomic variation: text, atlas, and world literature.** Baltimore: Munich, p. 607. 1988.

TONG, K.; GUIOT, L. P. Minimally invasive plate osteosynthesis of fractures of the radius and ulna in a primate. **Veterinary and Comparative Orthopaedics and Traumatology**, v. 26, n. 05, p. 416-420. 2013.

TORRES, A. A. A. *et al.* **Estudo observacional de afecções da superordem Xenarthra de vida livre e cativeiro no Brasil.** Dissertação de Mestrado. Universidade Federal de Minas Gerais. 2019.

