

Esophageal obstruction and rupture by a foreign body in a miniature mixed-breed heifer

Obstrução esofágica e ruptura por um corpo estranho em uma novilha miniatura de raça mista

Daniela Cortés-Beltrán¹ , César Augusto Pinzón-Osorio^{1,2*} , Carlos Vladimir Herrera-Luna¹ 

ABSTRACT: A 20-month-old miniature mixed-breed heifer weighing 200 kg was presented with a history of dysphagia, sialorrhea and dyspnea after being fed with food residues. At home it was treated with intravenous hydration, antibiotic combination, diuretics and AINEs. Additionally, one failed passage of oro-ruminal tube and several ruminal trocarizations were performed. At clinical examination the animal showed signs compatible with digestive obstruction, severe dyspnea and shock. Complete blood count showed leukocytosis with neutrophilia, left shift and lymphocytosis. Serum chemistry tests showed hyperlactatemia, hypokalemia, hypocalcemia, hyperglycemia and azotemia. Acid-base analysis indicated severe metabolic acidosis and respiratory alkalosis. Esophagoscopy was performed, during which the patient went into shock and died. In necropsy a complete middle third esophageal obstruction with rupture by a carrot was identified.

KEYWORDS: bovine; choke; human food residues; perforation.

RESUMO: Uma novilha miniatura de 20 meses de idade com 200 kg de peso foi apresentada com um histórico de disfagia, sialorréia e dispnéia após ter sido alimentada com resíduos alimentares. Na fazenda, foi tratada com hidratação intravenosa, combinação de antibióticos, diuréticos e AINEs. Além disso, uma passagem falhada do tubo oro-ruminal e várias trocas de ruminal foram realizadas. No exame clínico o animal mostrou sinais compatíveis com obstrução digestiva, dispnéia severa e choque. O hemograma completo mostrou leucocitose com neutrofilia, deslocamento esquerdo e linfocitose. Testes de química sérica mostraram hiperlactatemia, hipocalemia, hipocalcemia, hiperglicemia e azotemia. A análise ácido-base indicou acidose metabólica grave e alcalose respiratória. A esofagoscopia foi realizada, durante a qual o paciente entrou em choque e morreu. Na necropsia foi identificada uma obstrução completa do terço médio do esôfago com ruptura por uma cenoura.

PALAVRAS-CHAVE: bovino; estrangulamento; resíduos de alimentos humanos; perfuração.

INTRODUCTION

Esophageal disorders are relatively uncommon in large animals (HASKELL 2008; MARZOK et al., 2015). However, obstruction of the esophagus also known as choke, occurs when large or inadequately chewed material lodges in the lumen of the esophagus (VISHWANATHA et al., 2012). Esophageal obstruction (EO) is frequently encountered as clinical presentation in bovine (MARZOK et al., 2015) and is attributable to their feeding habits (HAVEN 1990; FRANCOZ et al., 2015). This pathology is defined as the partial or complete loss of esophageal lumen resulting in the inability to swallow effectively (SEMIEKA 2010; WHITEHEAD 2017). It often occurs where the esophagus

deviates or is slightly restricted at the area over the larynx, the thoracic inlet, the base of the heart, and immediately cranial to the diaphragmatic hiatus (FRANCOZ et al., 2015). Obstruction may be intraluminal or extraluminal in location (MARZOK et al., 2015; CONSTABLE et al., 2017). EO is considered an emergency and is fatally associated when the eructation of ruminal gases is impaired and severe free-gas bloat develops (HAVEN 1990; DIVERS; PEEK 2008; VISHWANATHA et al., 2012; MARZOK et al., 2015), which may be life threatening if not relieved in time (HAVEN 1990; MARZOK et al., 2015).

Intraluminal obstructions are often caused by ingestion and incomplete mastication of large feedstuff (HAVEN 1990;

¹Animal Health Department, Faculty of Veterinary Medicine and Animal Science, Universidad Nacional de Colombia, Bogotá DC, Colombia

²College of Veterinary Medicine, Universidade Federal do Rio Grande do Sul (UFRGS), Porto Alegre, Rio Grande do Sul, Brazil

*Corresponding author: capinzono@unal.edu.co

Received: 21/03/2021. Accepted: 03/05/2021

MARZOK et al., 2015; MAHESH et al., 2016) such as vegetables [e.g. turnips (MARZOK et al., 2015), potatoes (GOMEZ et al., 2014; MARZOK et al., 2015; MAHESH et al., 2016), corn cobs (GOMEZ et al., 2014; HAVEN 1990)] and solid fruit [e.g. apples (CONSTABLE et al., 2017; GOMEZ et al., 2014), mango (VISHWANATHA et al., 2012; MAHESH et al., 2016), orange (MAHESH et al., 2016)], ingestion of foreign objects (HAVEN 1990; GOMEZ et al., 2014; MAHESH et al., 2016), or a consequence of the administration of medicated boluses (HAVEN 1990; HASS 2010). EO by trichobezoars, phytobezoars and esophageal granulomas have also been reported in cattle (HASS 2010; MAHESH et al., 2016). Rare cases of extraluminal EO occur when pressure is exerted on the esophagus by neighboring organs, tissues or space occupying lesions (MAHESH et al., 2016).

The diagnosis is based on external palpation of the object lodged in the cervical esophagus (HASS 2010; VISHWANATHA et al., 2012; MAHESH et al., 2016), manual oral exploration (HASS 2010; MAHESH et al., 2016), the inability to pass an oro-ruminal tube (HASS 2010; VISHWANATHA et al., 2012; MAHESH et al., 2016), endoscopic evaluation (HASS 2010; VISHWANATHA et al., 2012; GOMEZ et al., 2014; MAHESH et al., 2016) and radiography of the esophagus (HASS 2010; MAHESH et al., 2016).

Double contrast radiography with barium (sterile sodium iodine contrast if esophageal perforation is suspect) and air helps to better identify the location and nature of the foreign body (HASS 2010). In cattle, esophageal rupture (ER) is most frequently associated with foreign body obstruction (HAVEN 1990). The object itself may perforate the esophagus, or the injudicious use of a probing or other instrument in attempts to relieve obstruction may result in laceration (HAVEN 1990). Long-standing EO with concurrent pressure necrosis can also result in secondary ER (HAVEN 1990). In this occasion, a case of cervical EO complicated with severe free-gas bloat and an ER in a miniature mixed-breed heifer is reported. This case of EO was caused by the incomplete mastication of large feed-stuff (a carrot). To the authors' knowledge, this is the first description of EO and its complications in a miniature cow.

CASE REPORT

Anamnesis

A 20-month-old miniature mixed-breed pregnant heifer weighing 200 kg was referred to the Large Animals Hospital with a history of 3 days of dysphagia, sialorrhea and dyspnea after being fed with human food residues. The heifer was treated on the farm with oral fluids, oral mineral oil, IV hydration, oxytetracycline, a penicillin-streptomycin combination, furosemide, flunixin meglumine and piroxicam. Additionally, one failed oral passage of an irrigation tube and 3 ruminal trocarizations were made.

Clinical finding

At clinical examination the animal showed severe depression, congested mucous membranes with a capillary refill time of 4 seconds, an eyeball sinking of 6 mm, a skinfold return time of 4 seconds, calculated dehydration (>10%), tachycardia (heart rate: 120 beats per minute), a respiratory rate of 22 breaths per minute, a mucopurulent nasal discharge, mixed dyspnea, orthopnea, diffuse crackles in both lungs, coarse crackles in the trachea and respiratory distress. In addition, the heifer had excessive salivation, ventral edema in the head, neck and chest, generalized subcutaneous emphysema that extended by the head, neck and left side (from the scapula to the paralumbar fossa), a marked left abdominal distension associated to a ping sound and ruminal amotility indicative of free-gas bloat (Figure 1). The second cervical third of the esophagus was obstructed at the passage of oro-ruminal probe, and a ruminal trocarization with a 14-gauge x 2-inch needle was performed with gas outlet for 17 minutes.

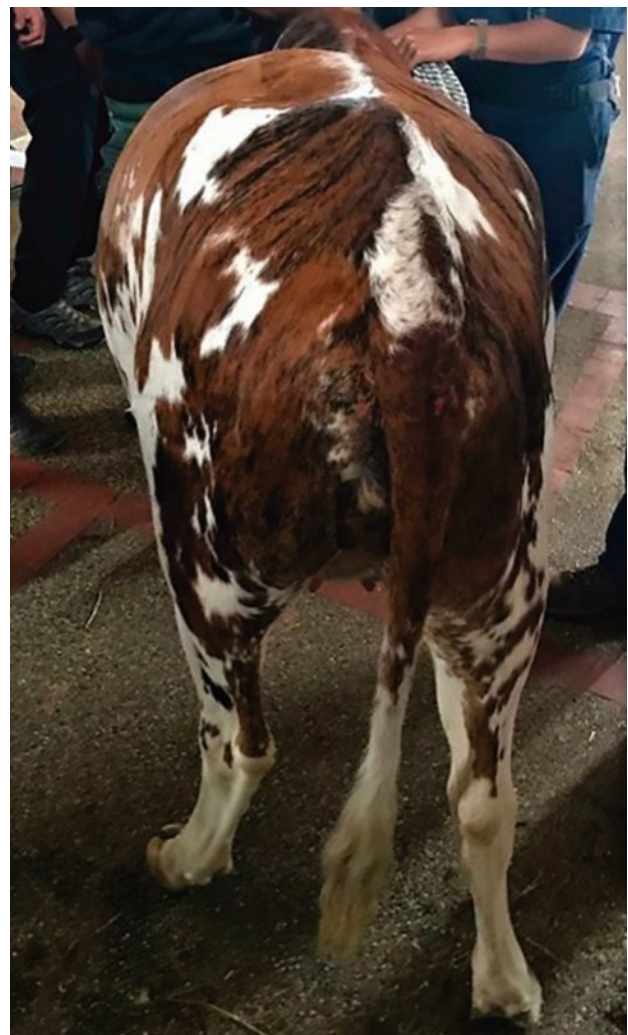

Figure 1. Severe bilateral abdominal distension. The left-sided distension is uniform and extends to the dorsal midline. Source: Author's collection.

Complete blood count (CBC) showed a severe leukocytosis with neutrophilia, left shift and lymphocytosis (Table 1) (JONES; ALLISON, 2007).

Serum chemistry tests showed severe hyperlactatemia, hypokalemia, hypocalcemia, hyperglycemia, azotemia, a mild increase in AST levels and hypobilirubinemia (Table 2) (RADOSTITS et al., 2006).

Acid-base analysis indicated a mixed disorder: metabolic acidosis by acid gain and respiratory alkalosis (Table 3)

Table 1. Results and normal values of Complete Blood Count and leukogram for cattle.

Parameter	Unit	Value	Reference interval
Hematocrit	%	40	22-40
Protein (Total Serum)	g/dL	78	6.7-7.4
Fibrinogen	mg/dL	200	300-700
White Blood Cells	cel/ μ l	22.900	4.000-12.000
Neutrophils	cel/ μ l	6.412	600-4.000
Lymphocytes	cel/ μ l	12.137	2.500-7.500
Eosinophils	cel/ μ l	916	0-2.400
Monocytes	cel/ μ l	458	25-800
Bands	cel/ μ l	2.977	0-120

Table 2. Results and normal values of serum chemistry for cattle.

Parameter	Unit	Value	Reference interval
Chloride	mmol/L	100	97-111
Sodium	mmol/L	137	132-152
Potassium	mmol/L	3.1	3.9-5.8
Calcium	mmol/L	0.62	2.43-3.10
Glucose	mg/dL	100	45-75
Lactate	mmol/L	11.52	0.6-2.2
Urea Nitrogen	mmol/L	23.9	2.0-7.5
Creatinine	μ mol/L	177.4	67-175
AST	U/l	191	78-132
Total Bilirubin	mg/dL	0.006	0.01-0.5
Direct Bilirubin	mg/dL	0.22	0.04-0.44
Indirect Bilirubin	mg/dL	0.23	0.01-0.5

Table 3. Results and normal values of acid-base analysis in venous samples for cattle.

Parameter	Unit	Value	Reference interval
pH	-	7.4	7.31-7.53
pCO ₂	mmHg	31.3	35-44
pO ₂	mmHg	87	35-53
Bicarbonate	mEq/L	18.7	17-29
Base Excess	mEq/L	-5.7	+1.1 +/- 3
Anion Gap	mEq/L	21	14-20

(BETANCUR et al., 2015). Esophagoscopy was performed under low sedation, showing a large amount of foam in the upper respiratory tract, severe congestion in the pharynx and larynx and bilateral edema of the arytenoid cartilages. An orange foreign body obstructing the cervical esophagus was observed, but it was not possible to reach the site of the obstruction, because the patient collapsed and died during the procedure.

Necropsy findings

At necropsy the heifer showed a swelling in the ventral neck region from the jaw to the entrance of the chest, severe bilateral abdominal distention, severe edema in the subcutaneous tissue at the submandibular region that extended up to the thorax, excess of cloudy yellowish fluid in the thorax and excess of serous fluid in the pericardium. The presence of a foreign body was determined in the middle third of the esophagus (Figure 2A) with complete perforation of the esophageal wall (Figure 2B), devitalization of peri-esophageal soft tissues and formation of compartments. The foreign body found in the esophageal lumen was a piece of raw carrot, which was large (7 cm long, 5 cm wide and 4 cm high) and caused a complete intraluminal esophageal obstruction. Fibrin exudate and multifocal purulent material were also identified throughout the

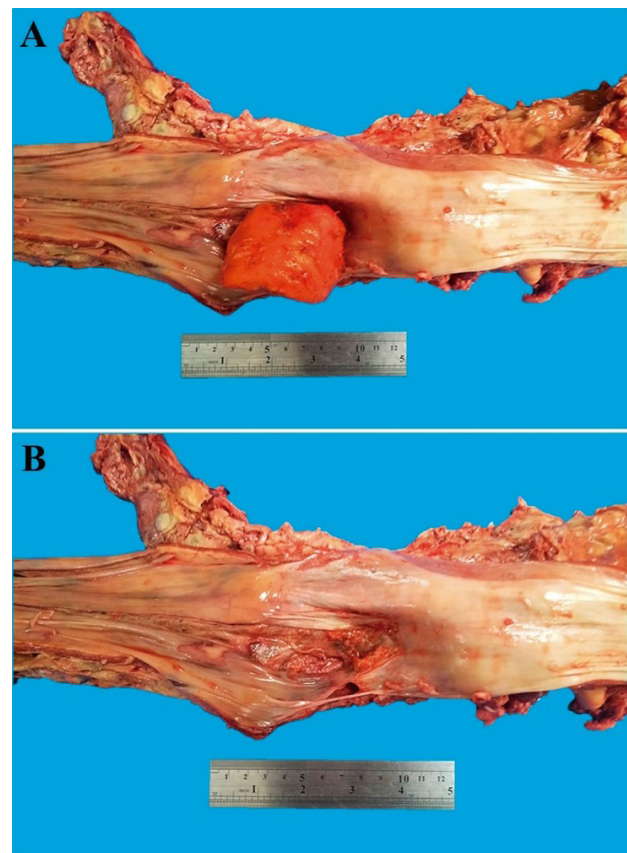


Figure 2. Gross necropsy findings of the esophagus. A. Complete middle third EO and rupture by foreign body (carrot). B. Devitalization of mucosa and peri-esophageal soft tissues. Source: Author's collection.

cervical ventral region of the esophagus with dehydration of the rumen, reticulum and omasum content.

Histologically, a severe esophageal transmural necrosis was identified with a severe mixed infiltrate of hyper segmented neutrophils, fibrin, severe hemorrhage and abundant colonies of basophilic bacteria with predominance of coccoid morphology and some bacillus in lower proportion.

According to historical facts and clinical examination as well as postmortem and histopathologic findings, a complete intraluminal EO by ingestion and incomplete mastication of large feedstuff (a carrot) with subsequent ER and bacterial contamination of local tissues was determined as a definitive diagnosis. The above-mentioned bacterial contamination being the main trigger of a septic process, leading to shock and death. In addition, a generalized severe lymphoplasmacytic and eosinophilic colitis with coccidial parasites (*Eimeria* spp.) and bacteria, as well as moderate lymphoplasmacytic enteritis were identified as a secondary source of origin and complicating factor of the mentioned sepsis.

DISCUSSION AND CONCLUSIONS

In bovine veterinary practice, EO caused by foreign objects is considered one of the most important emergency conditions, because it may be life threatening if not relieved in time. Bovines are more frequently affected by EO than other animals due to their peculiar feeding habits (MARZOK et al., 2015; PATIL et al., 2017). As some authors report, the ingestion of foreign bodies is extremely common in cattle, especially in animals that had been fed with corncobs, potatoes, apples, carrots, stones, or wood (GOMEZ et al., 2014; SMITH; GUARD 2015; PATIL et al., 2017). In the case presented, the EO was associated with the fact that the heifer was fed with human food residues, which is a risk factor reported in the literature.

EO requires immediate intervention, because the partial or complete loss of the esophageal lumen results in the inability to effectively swallow, which causes eructation blockage of ruminal gases and consequent severe free-gas bloat that can be fatal (RINGS 2009; VISHWANATHA et al., 2012; MARZOK et al., 2015; MAHESH et al., 2016; PATIL et al., 2017; WHITEHEAD 2017). In this case, severe free-gas bloat was observed and suspected for the subsequent tympanism that did not compromise the patient's life before it arrived at the hospital due to 3 ruminal trocarizations which had been performed on the farm.

In some cases, ER is frequently associated with foreign body obstruction, which can perforate the esophagus due to several factors including size, shape, weight, sharpness (SEMIEKA 2010), while in other cases it may be the result of the reckless use of an instrument used to try to relieve the obstruction (HAVE 1990). In this particular instance, the animal had an ER due the size, and the exposure time of foreign body inside the esophagus and the inadequate use of the irrigation tube to relieve the obstruction.

There are two forms of presentation in the EO reported in the literature. Extraluminal obstruction caused by esophageal diverticula, squamous cell carcinoma, papilloma, polyps, leucosis, abscess and tuberculosis (HASKELL 2008). On the other hand, intraluminal obstruction of the esophagus in ruminants may occur due to intake of whole vegetables (GOMEZ et al., 2014; MARZOK et al., 2015; MAHESH et al., 2016) and fruits (VISHWANATHA et al., 2012; GOMEZ et al., 2014; MARZOK et al., 2015; MAHESH et al., 2016), foreign objects (HAVE 1990; GOMEZ et al., 2014; MARZOK et al., 2015; MAHESH et al., 2016), trichobezoars, phyto-bezoars and esophageal granulomas. Other causes have been reported, like administration of medicated boluses (HAVE 1990; HASS 2010; MARZOK et al., 2015; MAHESH et al., 2016; PATIL et al., 2017). The EO in this heifer may have been favored by the incomplete swallowing and large-size of the intake carrot, as some authors reported in normal-sized cows that had intraluminal EO due to incomplete chewing of large-sized food (HAVE 1990, PATIL et al., 2017).

EO usually occurs with excessive salivation, an anxious expression, extended head and neck, bloat, and fever (DIVERS; PEEK 2008). Other authors have reported signs such as ptyalism, cough, nasal discharge with food content, orthopnea, dysphagia, ventral edema in the head, neck and chest, ventral emphysema (HAVE 1990), signs attributable to bloat like left-sided or bilateral abdominal distension, ping sound, respiratory distress (DIVERS; PEEK 2008), metabolic acidosis, dehydration, shock and death (HASS 2010; MCFARLANE; FLEMING 2015; MAHESH et al., 2016) as happened in the heifer in this case.

Diagnosis of EO is based on history such as recent intake of whole vegetables, fruits or foreign bodies, and clinical signs. In this particular case, the history of the patient confirmed what has been reported and showed all the clinical signs mentioned above. Thus, the main differential diagnosis was EO. External palpation of the foreign body may be used for confirmation when it is located in the cervical esophagus (HAVE 1990; MARZOK et al., 2015; PATIL et al., 2017). In the case presented here, this was not possible due to the severe generalized emphysema and edema in the ventral region of the neck. Other diagnostic tools reported that may help to identify the obstruction include manual exploration of the oral cavity, esophageal endoscopy (HAVE 1990; MARZOK et al., 2015; PATIL et al., 2017), stomach tubes or passing probangs (MARZOK et al., 2015; PATIL et al., 2017), esophageal ultrasonography (MARZOK et al., 2015) and non-contrast or contrast radiography of the cervical and thoracic esophagus (HAVE 1990; MARZOK et al., 2015; PATIL et al., 2017). In our case, the passage of an oro-ruminal probe shows that the esophagus was obstructed at the second cervical third, which was highly indicative of the presence of a foreign body generating an intraluminal EO. Additionally, the esophageal endoscopy showed an orange foreign body

(compatible with a carrot) obstructing the cervical esophagus, which allows to confirm the diagnosis. It was not possible to perform another diagnostic tool, because the patient died after the esophageal endoscopy.

The clinical pathology showed leukocytosis with neutrophilia and left shift. These parameters were associated with ER, which led to bacterial contamination of local tissues (phlegmon), as well as a possible secondary process of pneumonia by aspiration progressing to a septic process (WHITEHEAD 2017). In addition, the elevated hematocrit level could be associated with the dehydration (10%), produced by the inability of water and food intake during the 3 days of obstruction reported by the owners.

Prerenal azotemia causes a moderate to significant elevation of urea nitrogen in blood and creatinine and is caused by diseases that produce a reduction in effective circulating volume (GONZÁLEZ-MONTAÑA et al., 2017). In this case, severe dehydration could lead to a decrease in renal perfusion increasing serum concentrations of urea and creatinine. Otherwise, aspartate aminotransferase (AST) is an enzyme present in high concentrations in hepatocytes and muscle cells (skeletal and cardiac) of all species, and increased serum activity may result from lethal or sublethal injury to hepatocytes or muscle cells (ALLISON et al., 2012). In our case, the microscopic findings in the liver evidenced a slight hydrophilic degeneration and slight necrosis of focal coagulation that may have resulted from bacterial, viral, or parasitic infections (SMITH; GUARD 2015). Additionally, marked respiratory effort and esophageal injury may have contributed to its increase.

Hyponatremic ruminants increase serum aldosterone concentrations. The salivary gland responds by decreasing the concentration of Na⁺ in saliva and increasing that of K⁺, thus compensating for hyponatremia but leading to hypokalemia aggravated by non-consumption (BELL 1979; RIAD et al., 1986). In the same way, it is common to find electrolytic disorders due to continuous salivary losses, such as sodium and chloride deficits leading to continued loss of sodium bicarbonate and sodium phosphate in saliva (SMITH; GUARD 2015). In this case, the animal showed marked hyponatremia and hypochloremia due to the above mentioned.

Hyperglycemia may have resulted from the release of glucocorticoids from stress, which leads to a reduction in glucose uptake by insulin resistance at both the hepatic and peripheral levels and to inhibition of insulin secretion (MCFARLANE; FLEMING 2015). On the other hand, lactic acidosis as a cause of metabolic acidosis is associated with multiple causes that lead to tissue hypoperfusion associated with dehydration, hypotension caused by sepsis, blockage of venous return and severe ruminal tympanism (STÄMPFLI; MAGDESIAN 2015).

The reported treatments for EO include medical and surgical techniques. In the medical and manipulative treatment, the use of intravenous solution to hydrate and stabilize the patient is recommended, as well as antibiotic therapy with

trimethoprim sulfadoxine and flunixin meglumine, as reported by (GOMEZ et al., 2014). Moreover, the use of xylazine HC is indicated to sedate the animal and make it easier to handle and then push the obstructing object aborally towards the rumen by the use of a stomach tube, or to maneuver it orally, to be withdrawn from the mouth (MARZOK et al., 2015). Ruminal trocarization through the left paralumbar fossa can be performed to relieve ruminal tympany prior to attempting removal of the foreign body (HASS 2010; MARZOK et al., 2015). In this case, it was decided to make a trocarization in order to stabilize the patient and relieve the respiratory distress. Surgical intervention (esophagostomy or laparo-rumenotomy in some cases) is done when the medical and manipulative treatment to remove the foreign body have failed (GOMEZ et al., 2014; MARZOK et al., 2015).

The prognosis is good for animals that are treated within 2 to 12 h from the onset of clinical signs and worsens for those that are not well identified within 24 to 48 h from the beginning of obstruction (HASS 2010; MARZOK et al., 2015). For the heifer, the prognosis was bad due to the unsuccessful treatment, because despite the detected obstruction, it was not handled properly for 3 days on the farm. Additionally, the prognosis worsens when secondary ruminal tympany occurs as well as inflammation and necrosis of the esophageal mucosa (HASS 2010; MARZOK et al., 2015), like in this reported case.

The ER associated with foreign body obstruction showed in this case was produced by the injudicious use of an instrument in attempts to relieve the obstruction, as reported in the literature (HAVEN 1990; MAHESH et al., 2016; PATIL et al., 2017). It is suspected that the ER was associated with the failed passage of the oro-ruminal tube that had been done prior to the patient's arrival at the hospital. After perforation of the esophageal wall due to the foreign body, swelling develops quickly in the area of rupture as a result of edema and emphysema secondary to the gas produced in the rumen (HAVE 1990; UZAL et al., 2016). Moreover, the saliva and digested food accumulates in the subcutaneous tissue, leading to infection with coccoid bacteria of the surrounding tissues, mediastinitis, pleuritis, and possibly septicemia (HAVE 1990; PANZIERA et al., 2015). The severe deterioration of the clinical status of the patient resulting in shock, collapse and death was associated with ER, secondary bacterial infection of the periesophageal tissue and possible septicemia as indicated by postmortem and histological findings.

In conclusion, this report describes EO caused by a foreign body in a miniature mixed-breed heifer for the first time. Currently, cases of EO are rare in intensive farms due to reduced risk factors associated with food particle size and foreign object access. However, this case was associated with the fact that the heifer had been handled like a pet; as a result, it was fed with human food residues, so it is important to warn small farmers about risks of this practice to avoid new cases. Food size particles for miniature cows should be much

smaller than those for a normal cow, since particles of small to moderate size may lead to EO, so it is important to raise awareness in owners of miniature cattle. Prognosis of EO depends directly on a quick diagnosis, as well as opportune patient stabilization and adequate treatment.

Therefore it is key to educate students and veterinarians about the importance of esophageal diseases in ruminants as well as the associated risk factors. In addition, care must be

taken when performing the passage of oro-ruminal tube in cattle with EO, so as not to perforate the compromised esophagus.

ACKNOWLEDGEMENTS

The authors would like to thank Dr. Lucia Botero, for contributions to the pathological work-up of this case. We would also like to thank Dr. Rafaela Dimmel and Dr. Sandra Bednar for their assistance with this publication.

REFERENCES

- ALLISON, R.W. et al. Laboratory evaluation of the liver. In: THRALL, M.A.; WEISER, G.; ALLISON, R.W.; CAMPBELL, T.W. (Ed). **Veterinary hematology and clinical chemistry**. Wiley-Blackwell: Iowa, USA, 2012. pp. 405-406.
- BELL, F.R. The metabolic effects of sodium depletion in calves on salt appetite assessed by operant methods. **The Journal of Physiology**, v. 295, p. 431-443, 1979.
- BETANCUR, C. et al. Physiology of acid-base balance in bovines with diarrhea backgrounds from Monteria, Colombia. **Rev. MVZ Córdoba**, v. 20, n. 2, p. 4591-4601, 2015.
- CONSTABLE, P.D. et al. Diseases of the alimentary tract-ruminant. In: CONSTABLE, P.D.; HINCHCLIFF, K.W.; STANLEY, H.D.; GRÜNBERG, W. (Ed). **Veterinary medicine: A textbook of the diseases of cattle, horses, sheep, pigs, and goats**. Elsevier: Missouri, USA, 2017. pp. 436-621.
- DIVERS, T.; PEEK, S. Non-infectious diseases of the gastrointestinal tracts. In: DIVERS, T.J.; SIMON, F.P. (Ed). **Rebhun's diseases of dairy cattle**. Saunders Elsevier: St. Louis, Missouri, 2008. pp. 135-137.
- FRANCOZ, D.; FECTEAU, G.; DESROCHERS. Diseases of the alimentary tract. Acute abdomen in Ruminants. In: SMITH, B.P. (Ed). **Large animal internal medicine**. Elsevier Mosby: Missouri, USA, 2015. pp. 804-805.
- GOMEZ, D.E. et al. Endoscopic removal of esophageal and ruminal foreign bodies in 5 Holstein calves. **Canadian Veterinary Journal**, v. 55, n. 10, p. 965-969, 2014.
- GONZÁLEZ-MONTAÑA, J.R.; MARTIN, M.J.; ALONSO, P. General aspect and current fluid therapy in cattle with digestive disease. **American Journal of Animal and Veterinary Sciences**, v. 12, n. 3, p. 111-131, 2017.
- HASKELL, S.R.R. Esophageal disorders. In: CHASE, C.; LUTZ, K.; MCKENZIE, E.; TIBARY, A. (Ed). **Blackwell's five-minute veterinary consult: Ruminant**. Wiley-Blackwell: Iowa, USA, 2008. pp. 338-339.
- HASS, J. Esophageal foreign body in a 2-day-old calf. **Canadian Veterinary Journal**, v. 51, n. 4, p. 406-408, 2010.
- HAVEN, L.M. Bovine esophageal surgery. **Veterinary Clinics of North America: Food Animal Practice**, v. 6, n. 2, p. 359-369, 1990.
- JONES, M.L.; ALLISON, R.W. Evaluation of the ruminant complete blood cell count. **Veterinary Clinics of North America: Food Animal Practice**, v. 23, n. 3, p. 377-402, 2007.
- MAHESH, V. et al. Clinical management of esophageal choke - A clinical study of 25 cattle. **Intas. Polivet**, v. 17, n. 2, p. 607-610, 2016.
- MARZOK, M. et al. Esophageal obstruction in water buffalo (*Bubalus bubalis*): a retrospective study of 44 cases (2006-2013). **Turkish Journal of Veterinary and Animal Sciences**, v. 39, n. 2, p. 233-240, 2015.
- MCFARLANE, D.; FLEMING, S.A. Endocrine and metabolic diseases. In: SMITH B.P. (Ed). **Large Animal Internal Medicine**. Elsevier Mosby: Missouri, USA, 2015. pp. 1244-1252.
- PANZIERA, W. et al. Timpanismo em bovinos, secundário à obstrução esofágica por *Citrus limon* (limão siciliano). **Pesquisa Veterinária Brasileira**, v. 36, n. 5, p. 397-400, 2015.
- PATIL, A.S.; BALAGANUR, V.; CHAUHAN, V.L. Retrospective studies on occurrence and surgical management of esophageal obstruction in bovines. **Intas. Polivet**, v. 18, n. 2, p. 286-292, 2017.
- RADOSTITS, O.M. et al., In: CONSTABLE, P.D.; HINCHCLIFF, K.W.; STANLEY, H.D.; GRÜNBERG, W. (Ed). **Veterinary Medicine. A textbook of the diseases of cattle, horses, sheep, pigs and goats**. Saunders Elsevier: Missouri, USA, 2006. pp. 2051-2056.
- RIAD, F. et al. Aldosterone regulates salivary sodium secretion in cattle. **Journal of Endocrinology**, v. 108, n. 3, p. 405-411, 1986.
- RINGS, D.M. Esophageal Obstructions/Choke. In: RINGS, D.M.; ANDERSON, D. (Ed). **Current veterinary therapy: Food animal practice**. Saunders Elsevier: Missouri, USA, 2009. pp. 8-9.
- SEMIEKA, M.A. Radiography of unusual foreign body in Ruminants. **Veterinary World**, v. 3, n. 10, p. 473-475, 2010.
- SMITH, B.; GUARD, C.L. Diseases of the alimentary tract. Choke and esophageal disorders. In: SMITH, B.P. (Ed). **Large Animal Internal Medicine**. Elsevier Mosby: Missouri, USA, 2015. pp. 765-767.
- STÄMPFLI, H.; MAGDESIAN, G. Critical Care and Fluid Therapy. In: SMITH, B.P. (Ed). **Large Animal Internal Medicine**. Elsevier Mosby: Missouri, USA, 2015. pp. 1371-1372.
- UZAL, F.A.; PLATTNER, B.L.; HOSTETTER, J.M. 2016. Alimentary System. In: MAXIE, M.G. (Ed). **Jubb, Kennedy Palmer Pathology of Domestic Animals**. Elsevier: Missouri, USA. pp. 1-257.
- VISHWANATHA, B. et al. Choke in a cow -A case report. **Veterinary World**, v. 5, n. 1, p. 40-41, 2012.
- WHITEHEAD, A. Esophageal disorders. In: CHASE, C.; LUTZ, K.; MCKENZIE, E.; TIBARY, A. (Ed). **Blackwell's five-minute veterinary consult: Ruminant**. Wiley-Blackwell: Iowa, USA, 2017. pp. 332-334.

